



CT Sectional Anatomy

TOM HALLER, RT (R)(CT)(MR)

Anatomy of the Skull

BETHESDA OAK HOSPITAL
PQ5000 8999
22-Jan-98 06:10
PHANTOM
ID: 000
CONT: NONE

ANT

2-D #5
Active

Loc: 309 mm
X : -0.5 mm
Y : 17.3 mm
Z : -302.2 mm
Zoom: 2.76 X



Mandibular Condyle

Mastoid Process

Foramen Ovale

Foramen Spinosum

Hypoglossal canal

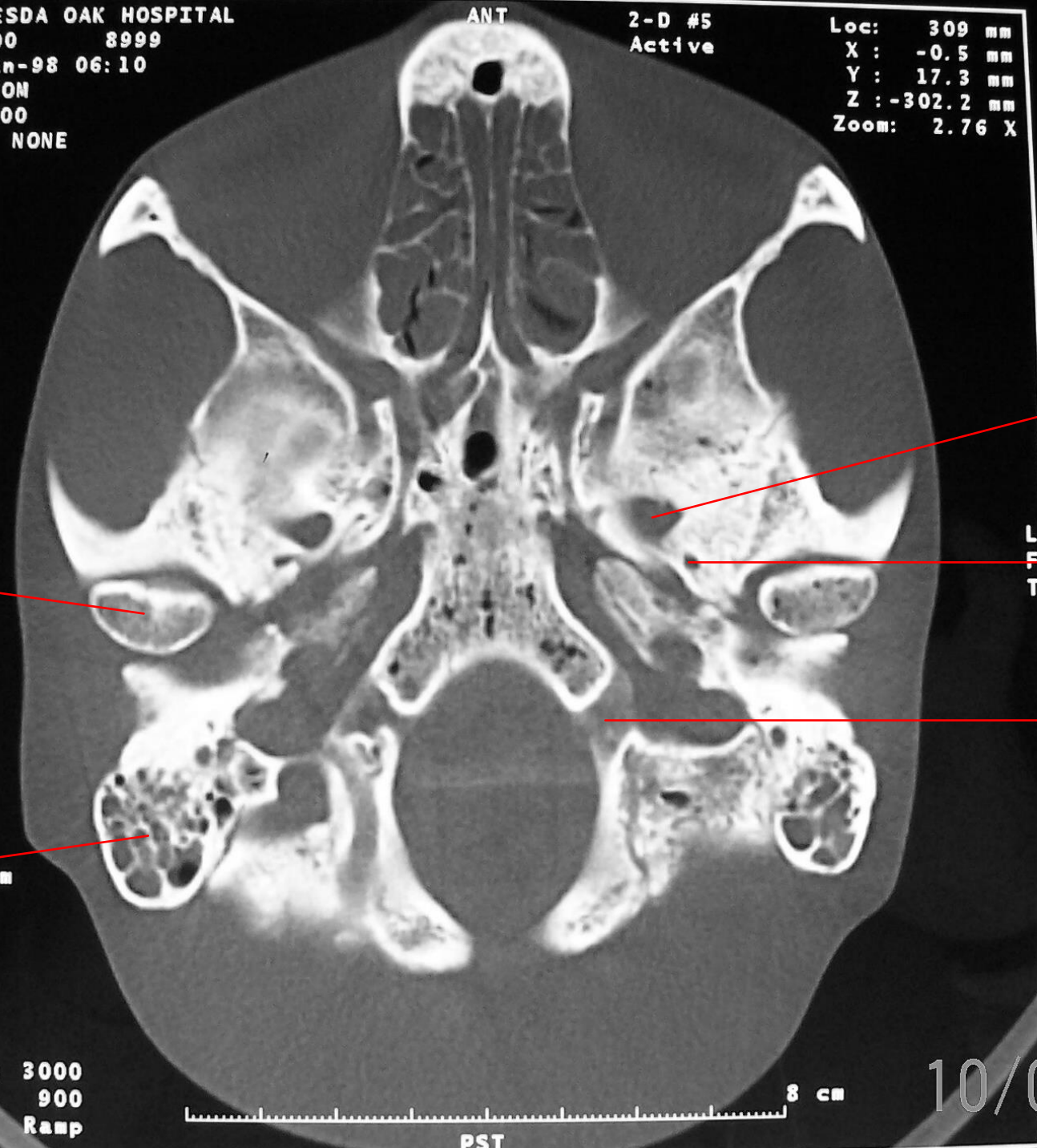

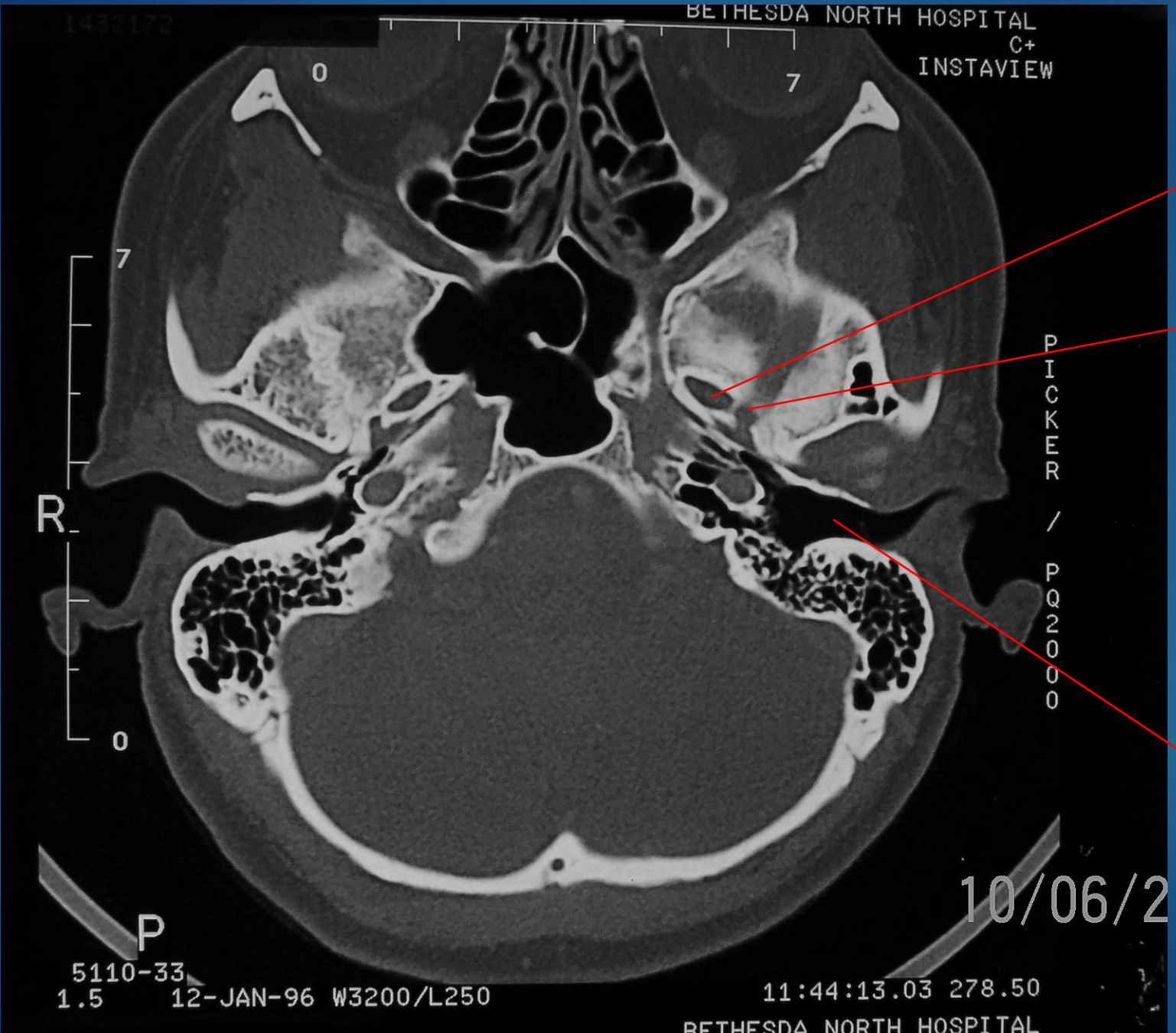
Window: 3000
Level: 900
Map: Ramp

PST

8 cm

10/0



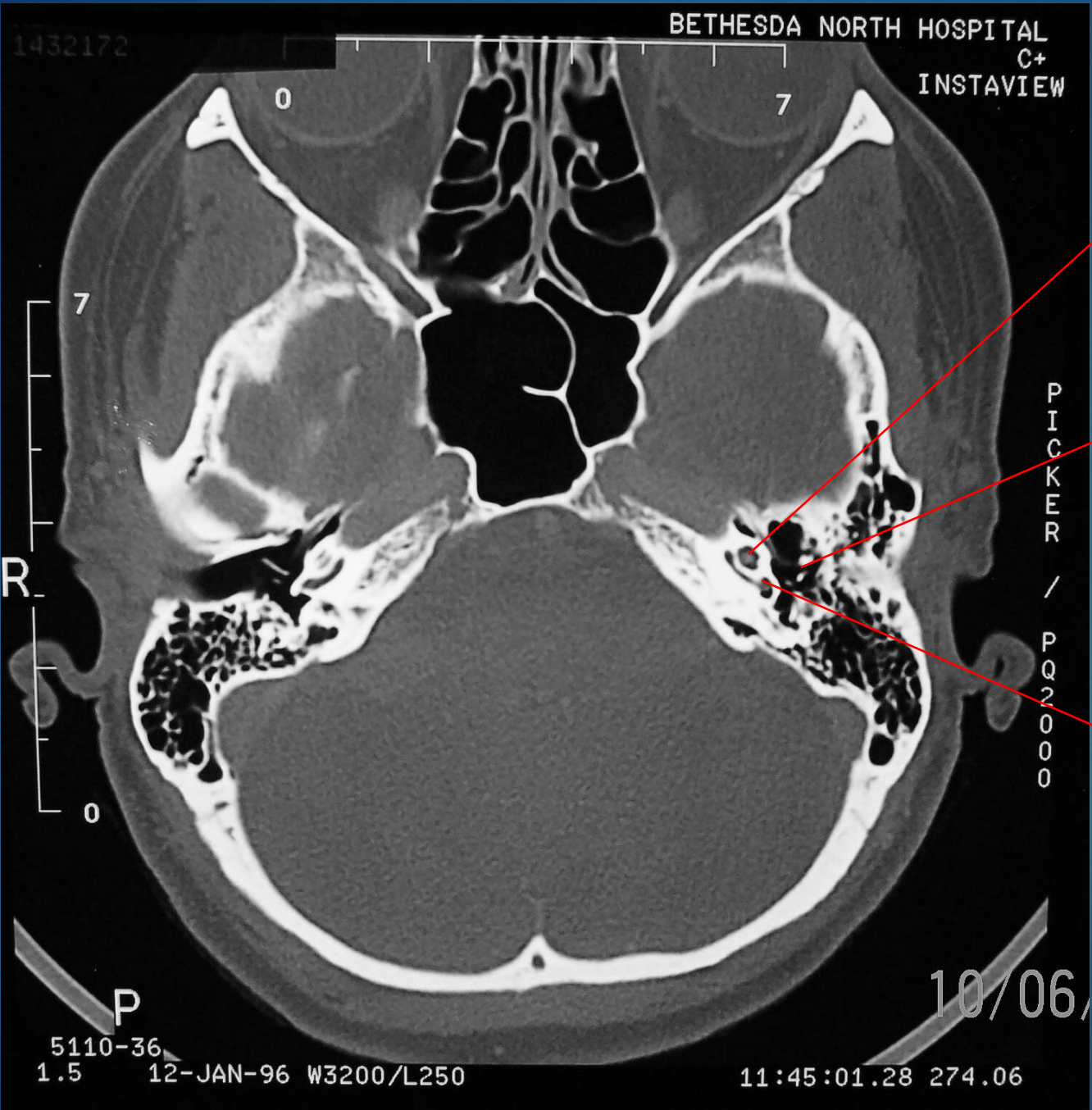


Foramen Ovale

Foramen spinosum

External auditory meatus

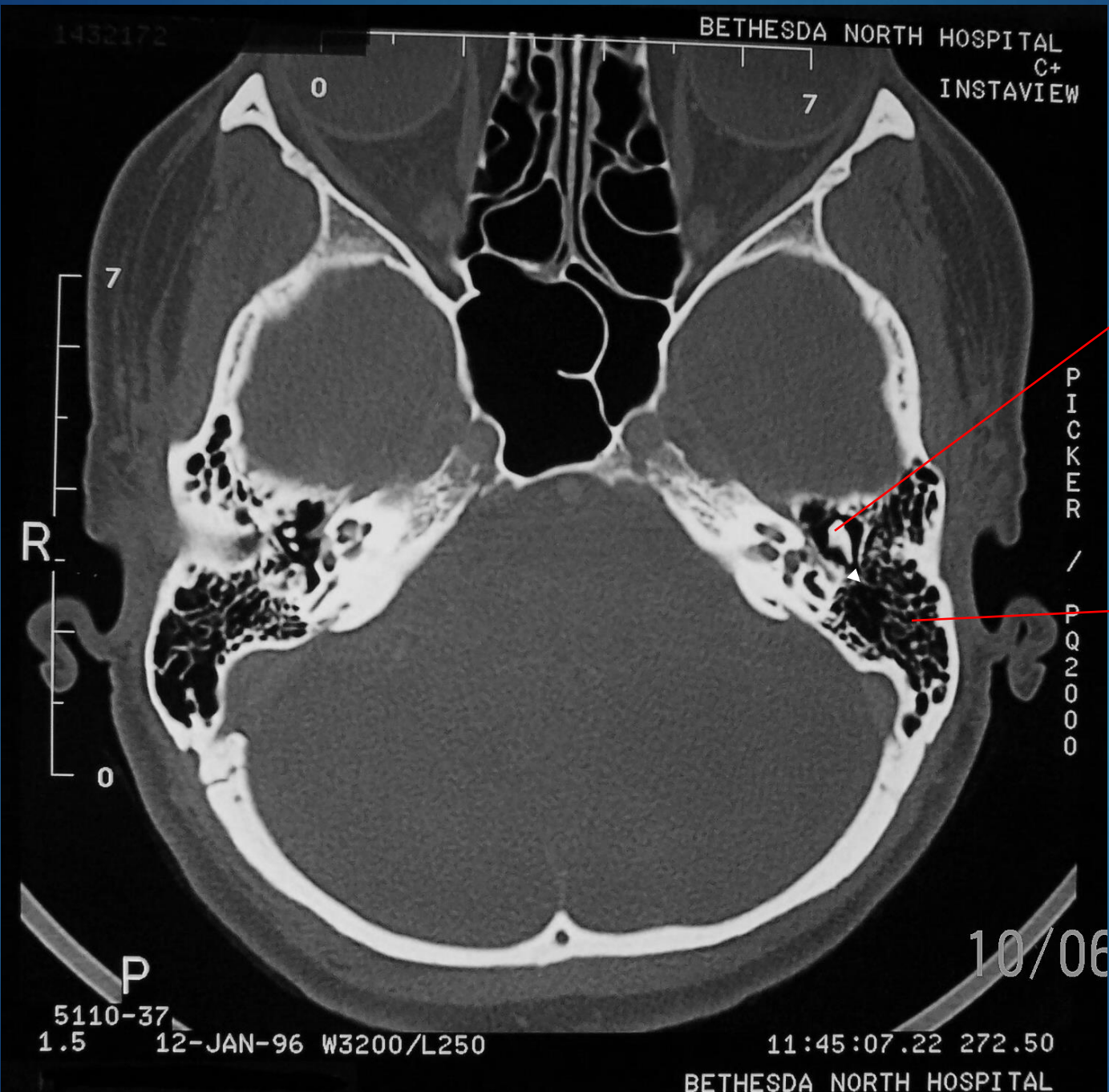




cochlea

Ossicles in middle ear cavity

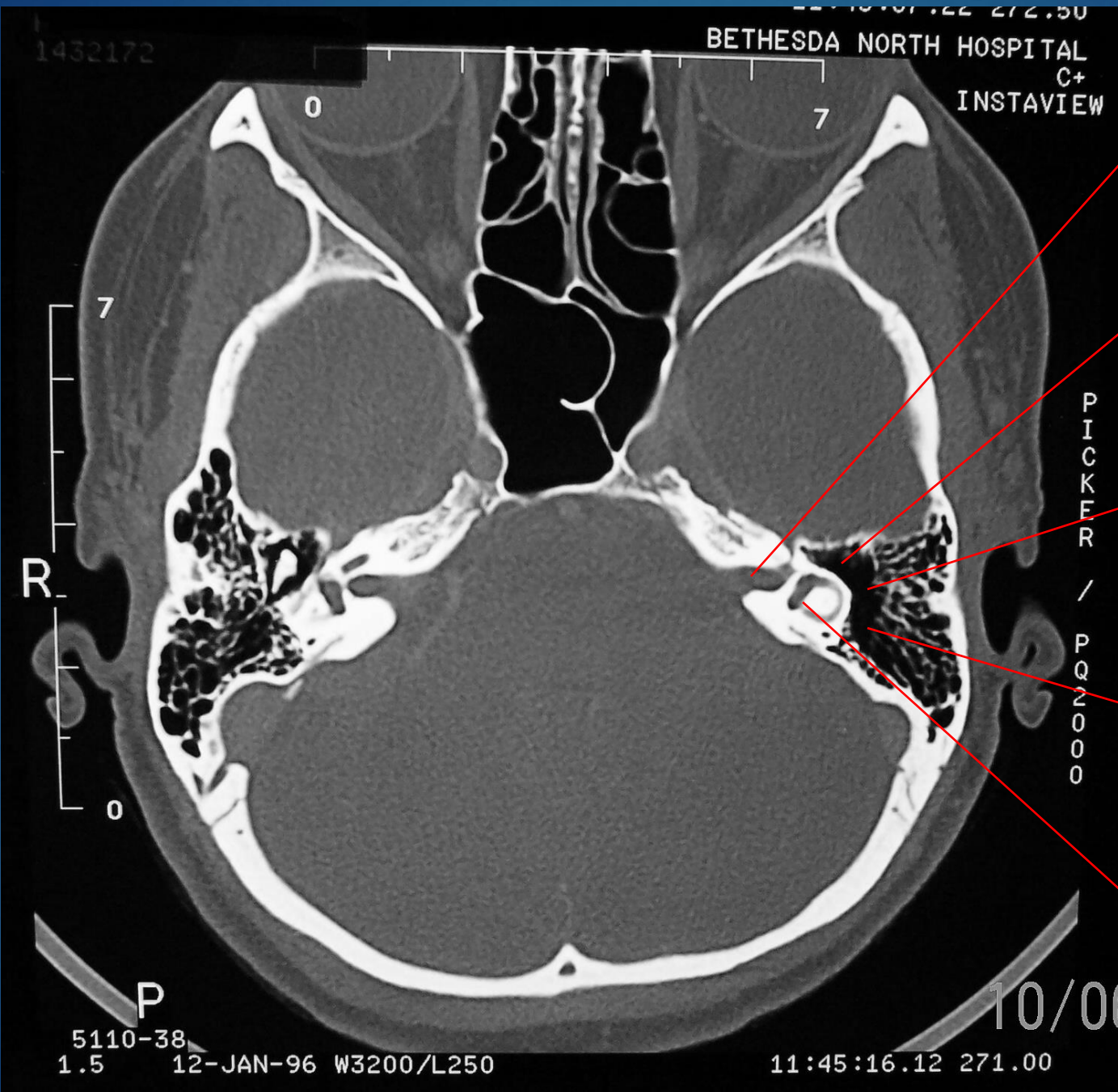
vestibule



ossicles

Mastoid air cells





Internal auditory meatus

attic

additus

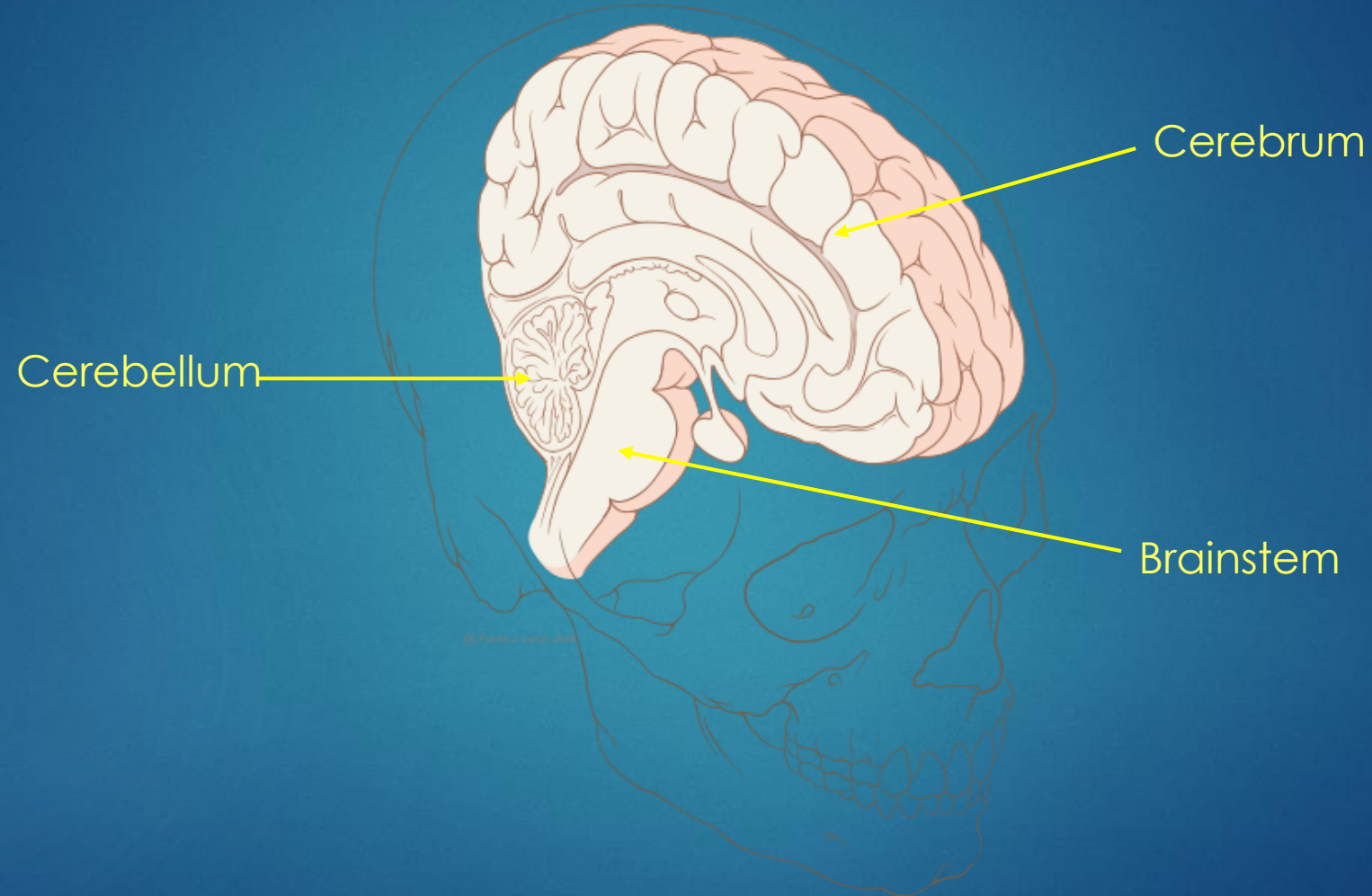
Mastoid antrum

Semicircular canals

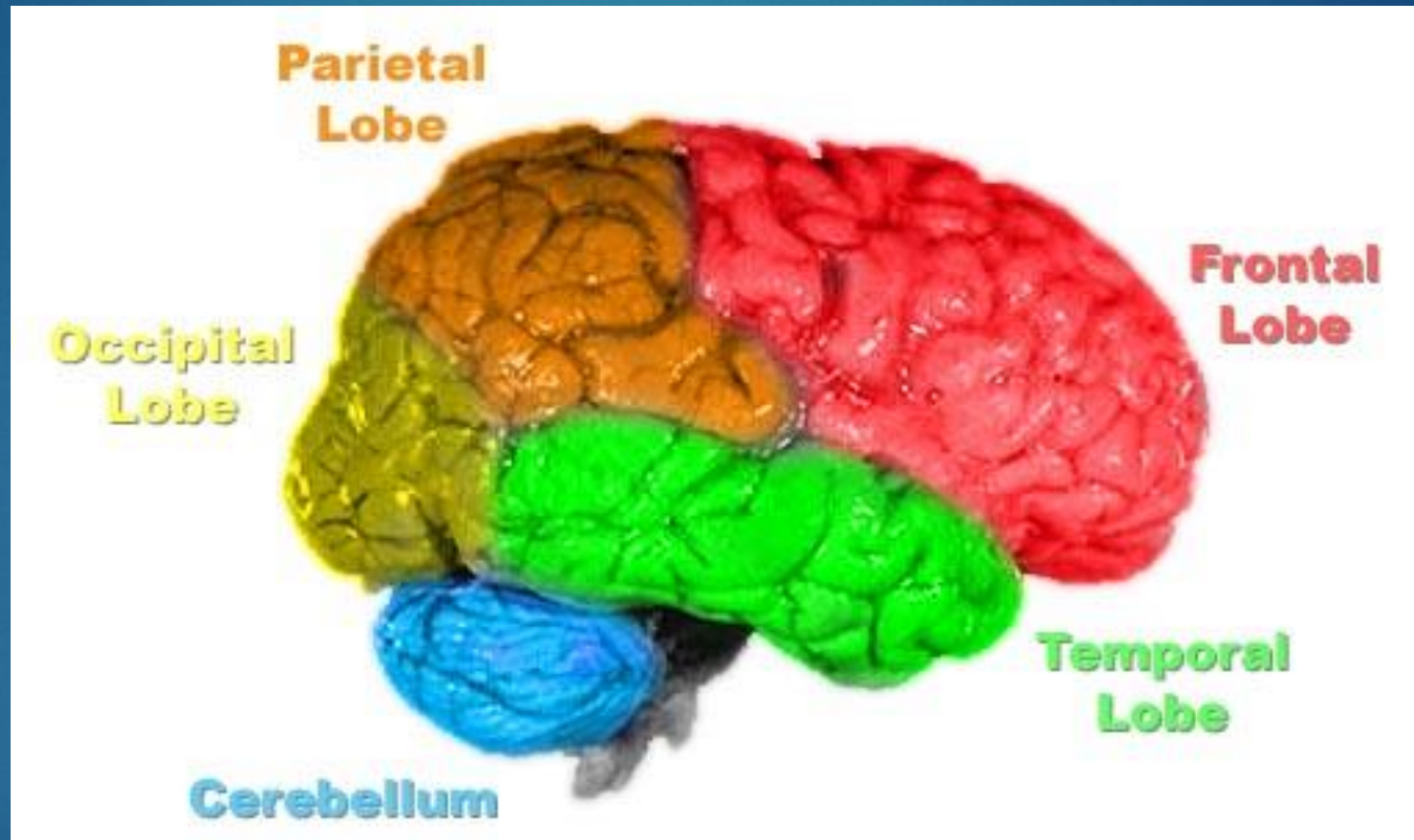


Anatomy of the Brain

Major Divisions of the Brain

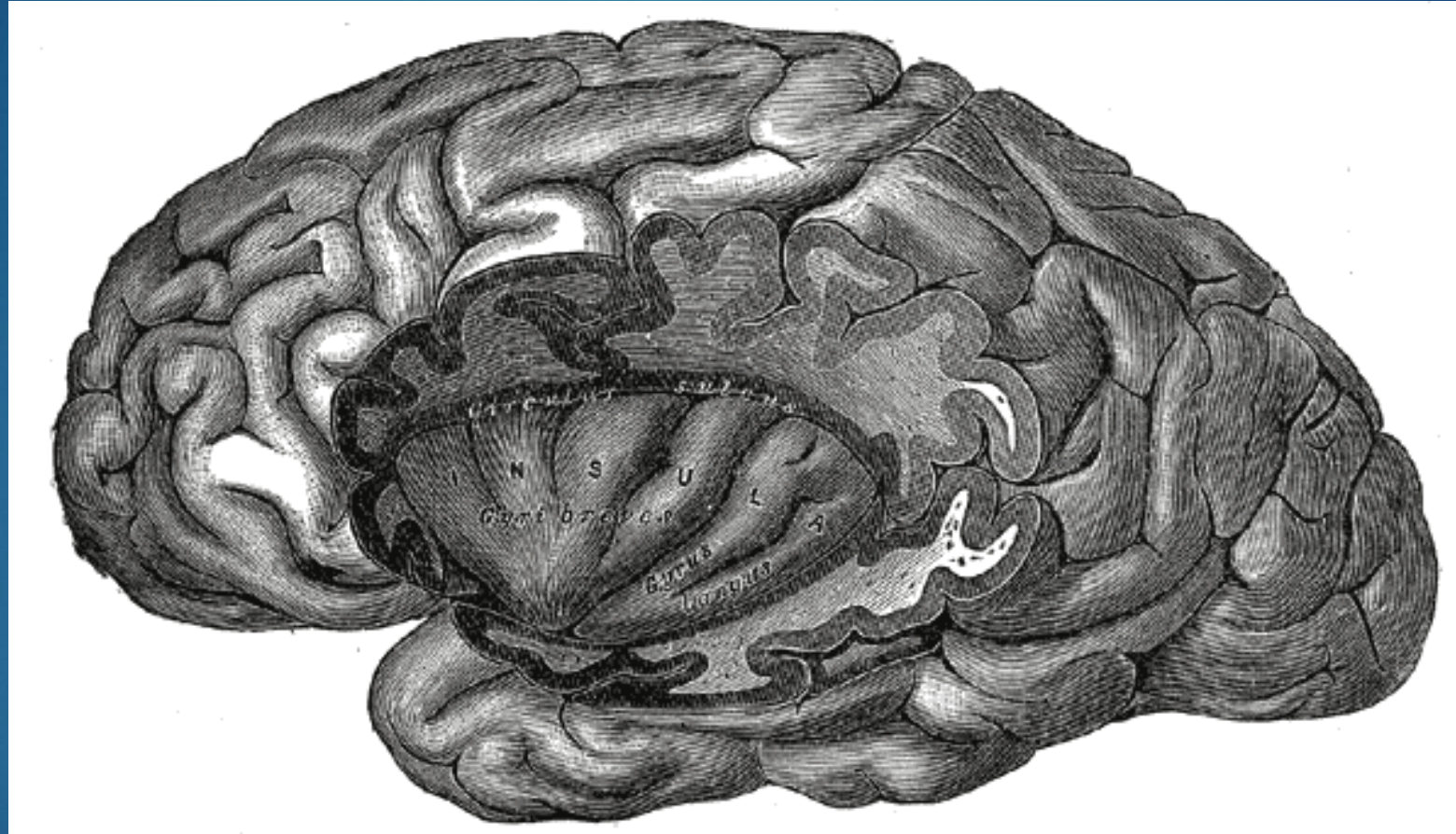

Outer Lobes of the Cerebrum, including the Cerebellum

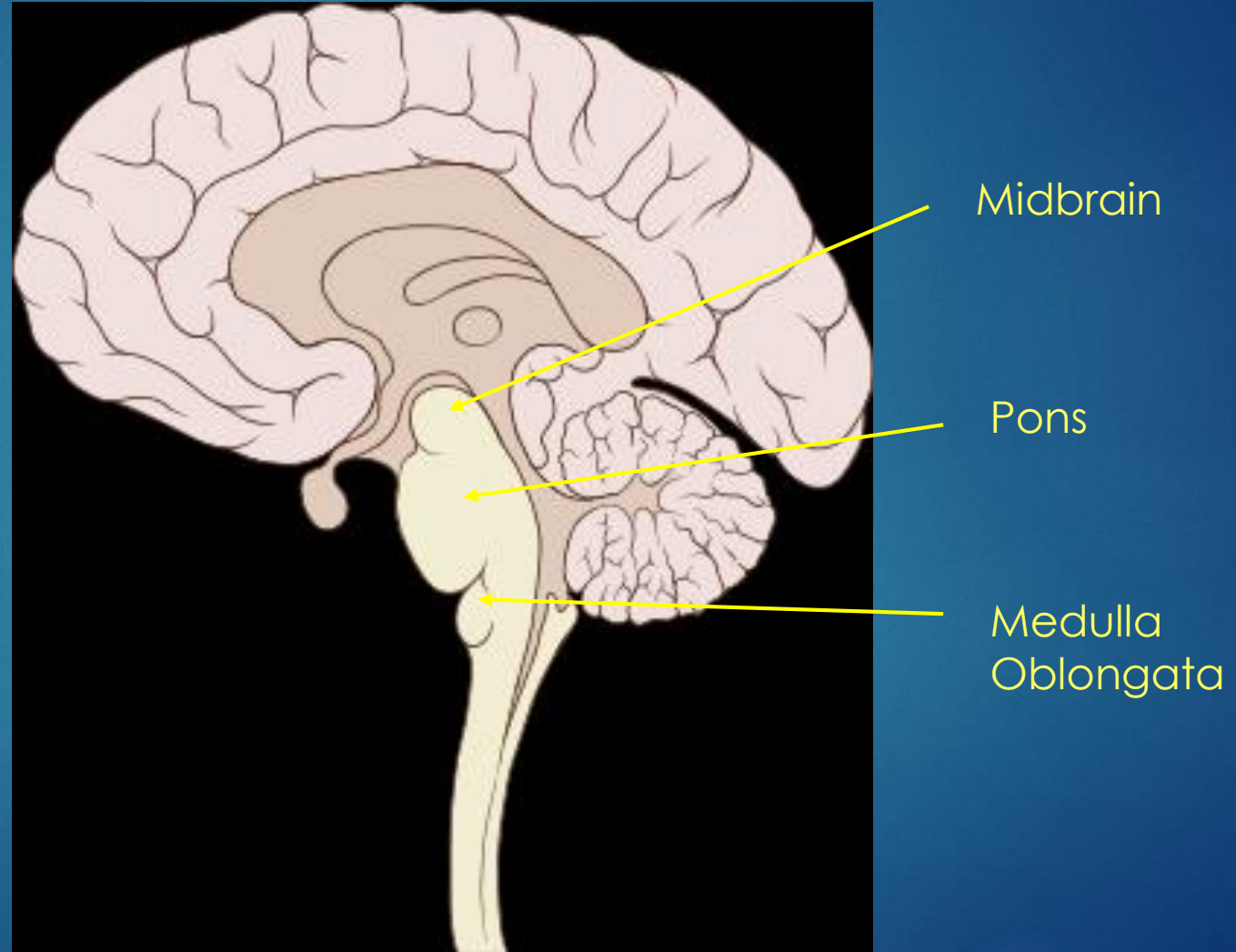


Lobes of the brain, color-coded. Based on [Image:Human brain NIH.jpg](#).

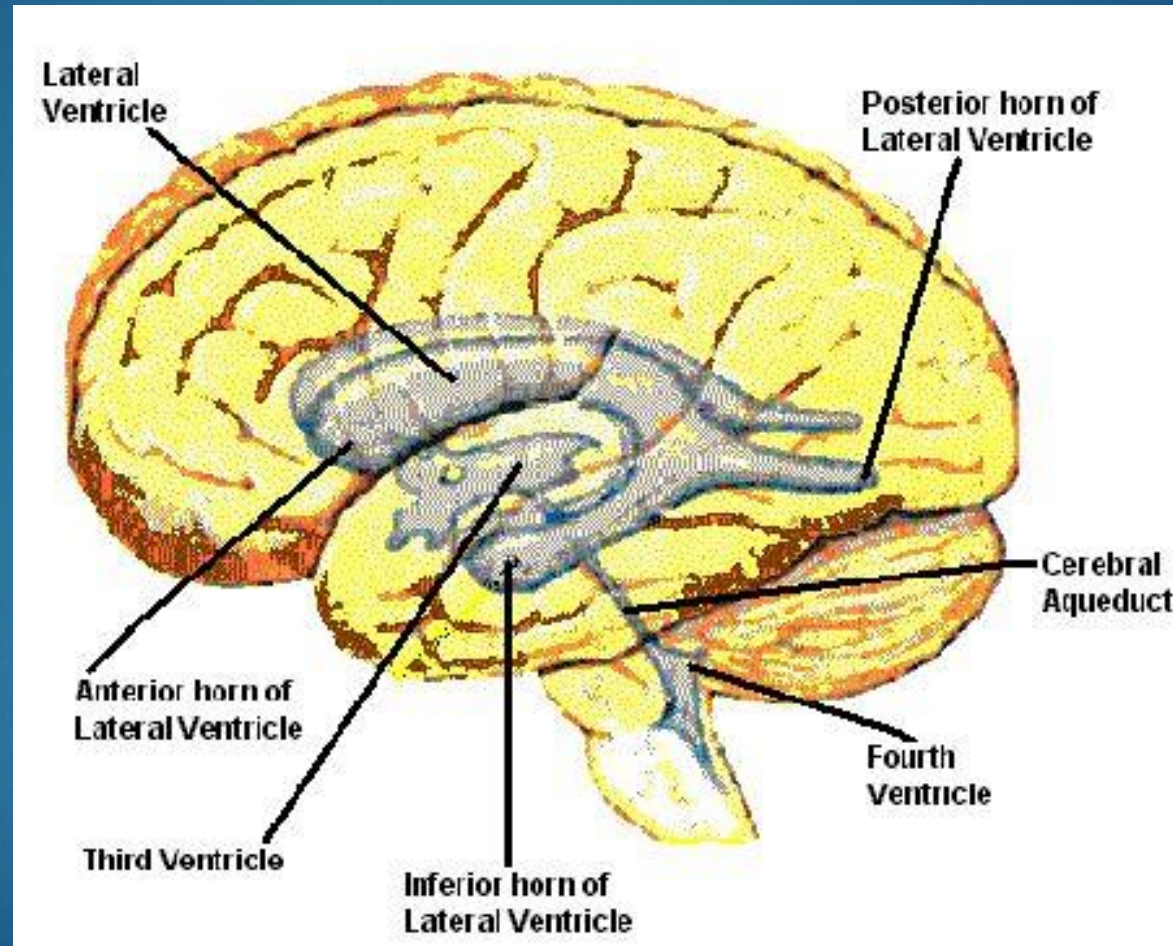
The Insular lobe of the Cerebrum



Portions of the Brainstem

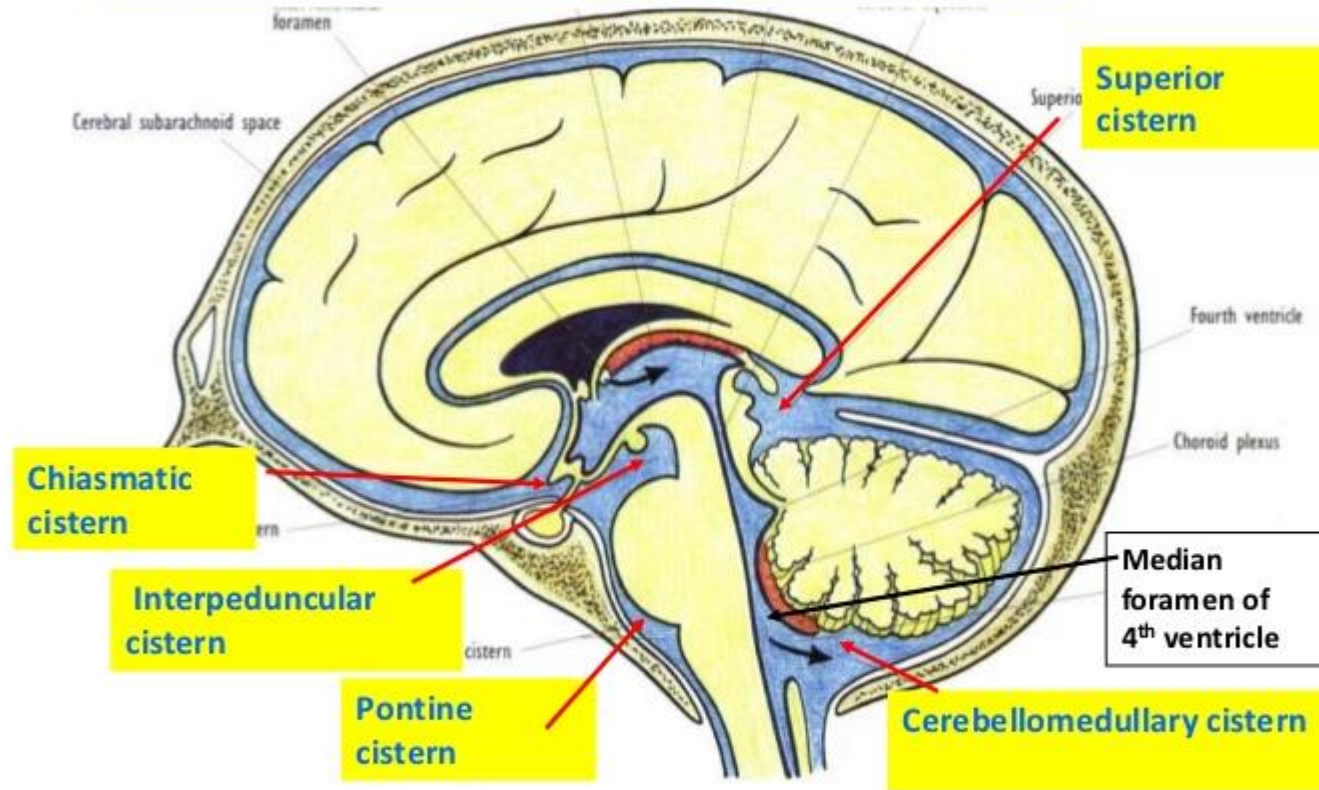


The Ventricular System



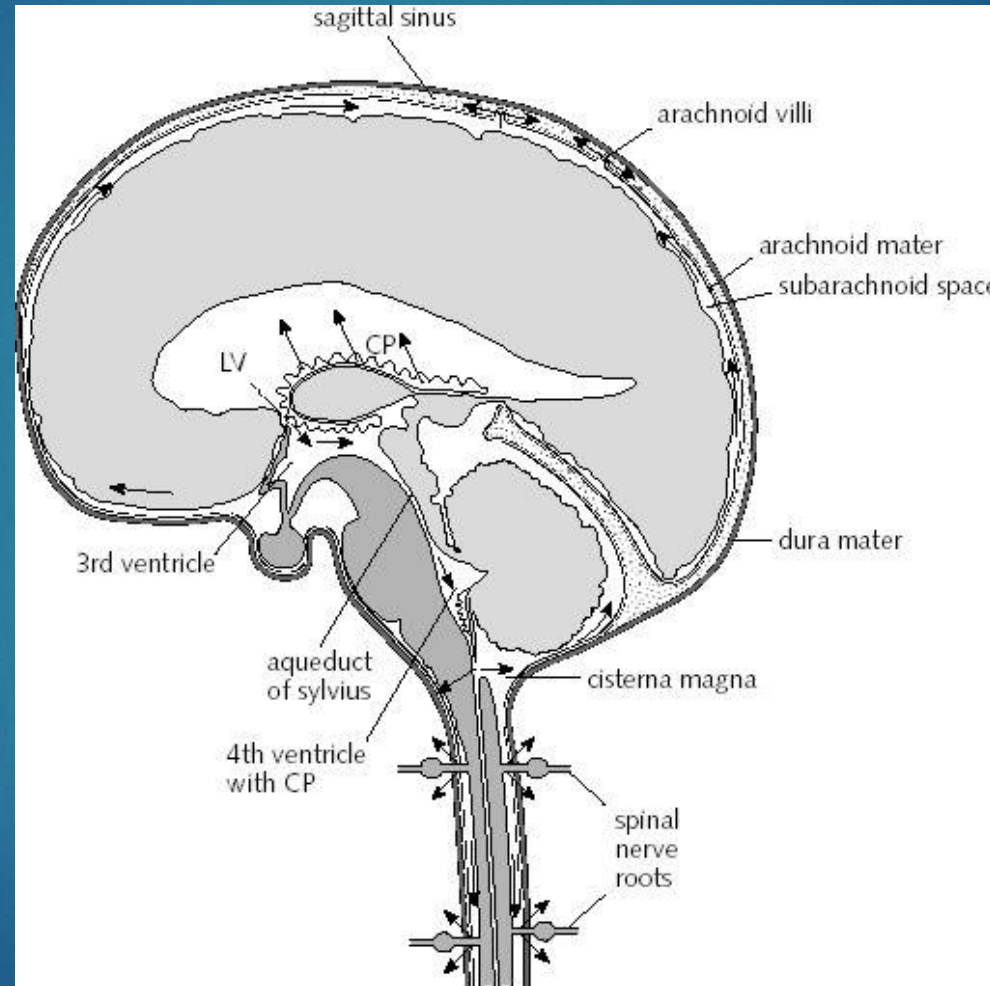
The cisternal system

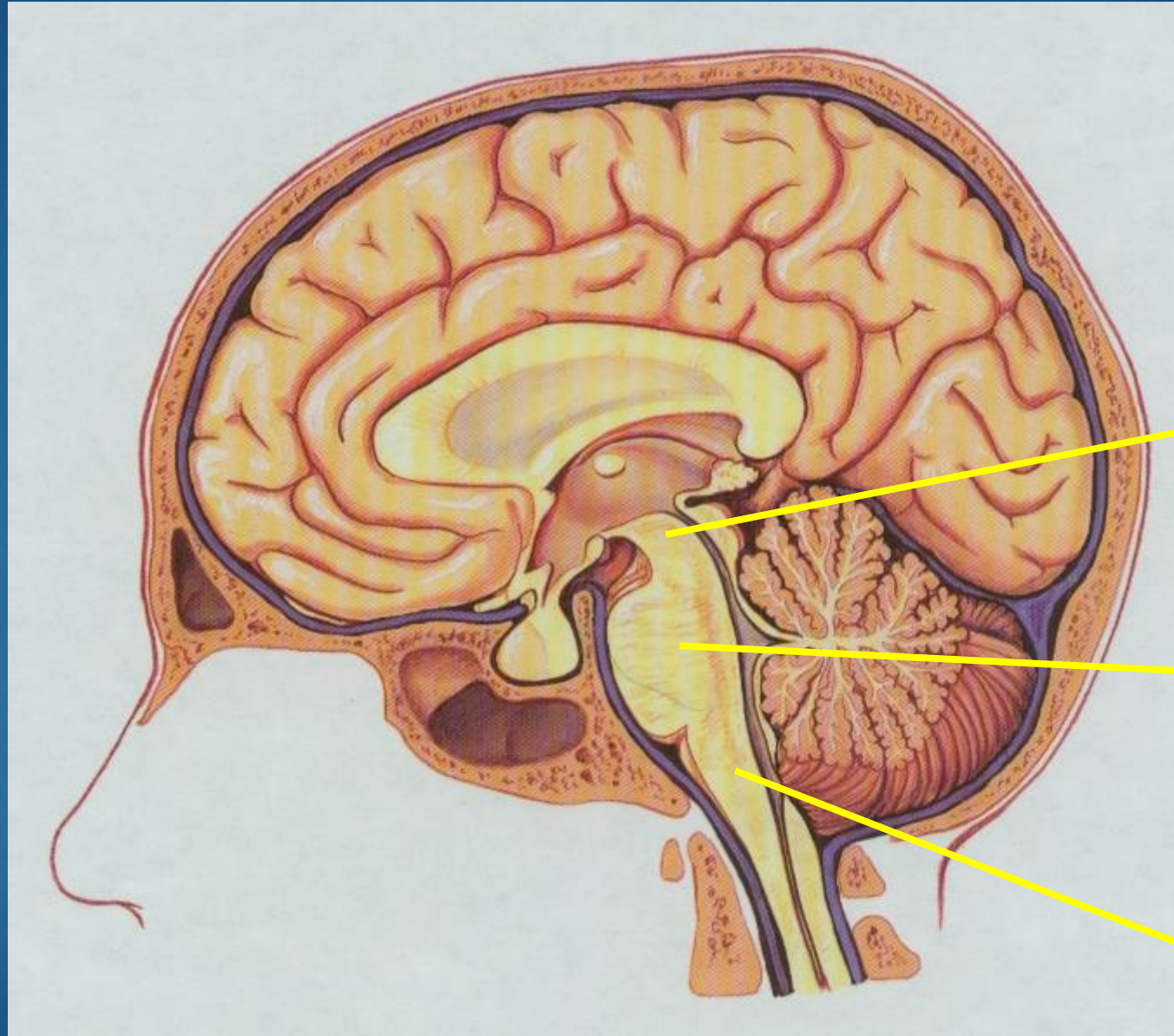
Circulation of CSF in subarachnoid space :



Median sagittal section to show the subarachnoid cisterns & circulation of CSF

Flow of CSF around the Brain





Midbrain

Pons

Medulla

BETHESDA OAK HOSPITAL
PQ2000 2419
28-Nov-95 15:51
Patient Name
ID: 0205468
CONT: C+

ANT

2-D #34
Not 3D-able

Loc: 207 mm
X: -1.4 mm
Y: 11.1 mm
Z: -207.4 mm
Zoom: 2.07 X

Calc. choroid
plexus

Lat vent

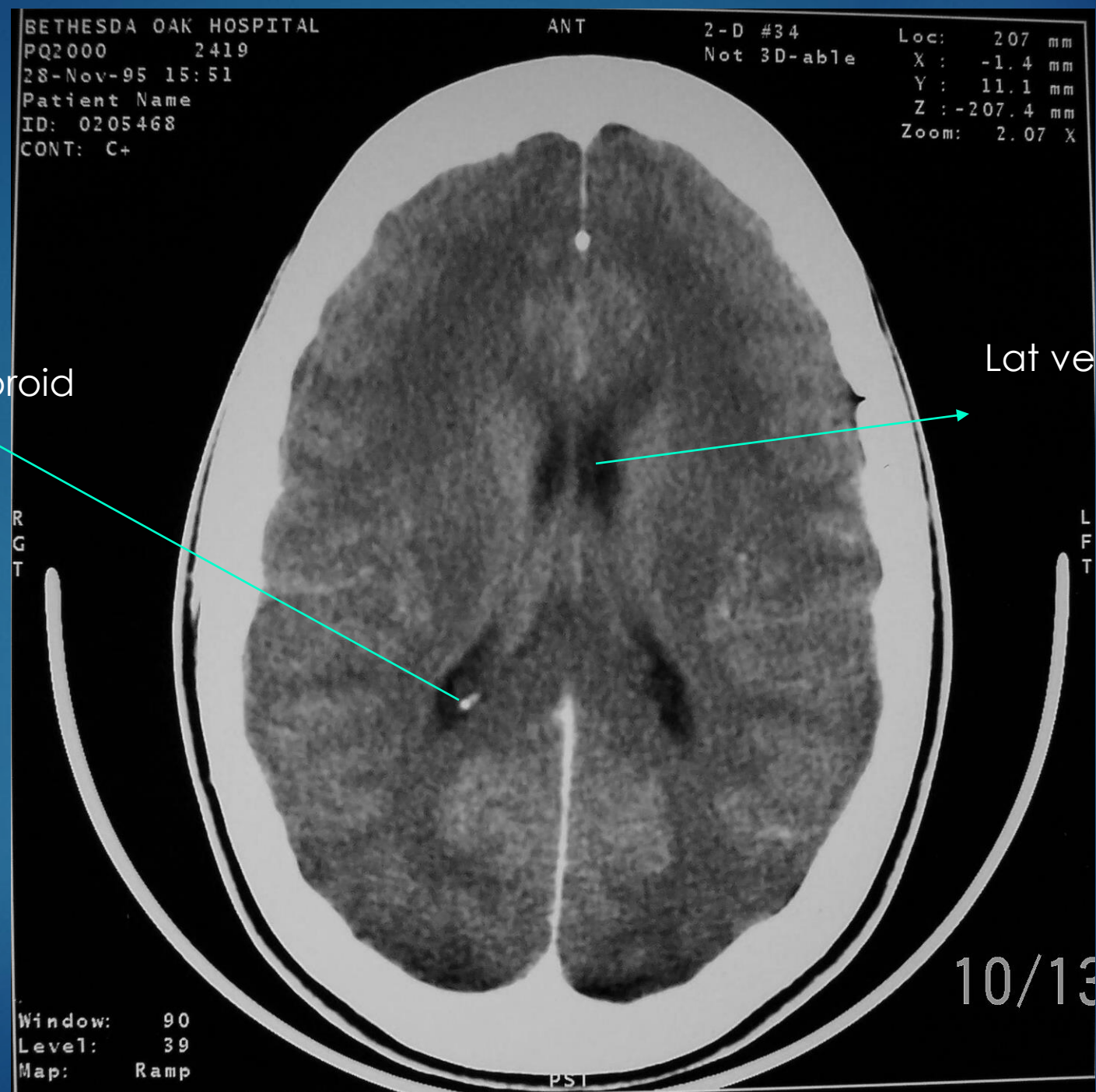R
G
T

L
F
T

Window: 90
Level: 39
Map: Ramp

10/13

PSI



BETHESDA OAK HOSPITAL
PQ2000 2419
28-Nov-95 15:51
Patient Name
ID: 0205468
CONT: C+

ANT

2-D #33
Not 3D-able

Loc: 215 mm
X: -1.4 mm
Y: 11.1 mm
Z: -215.4 mm
Zoom: 2.07 X

R
G
T

L
F
T

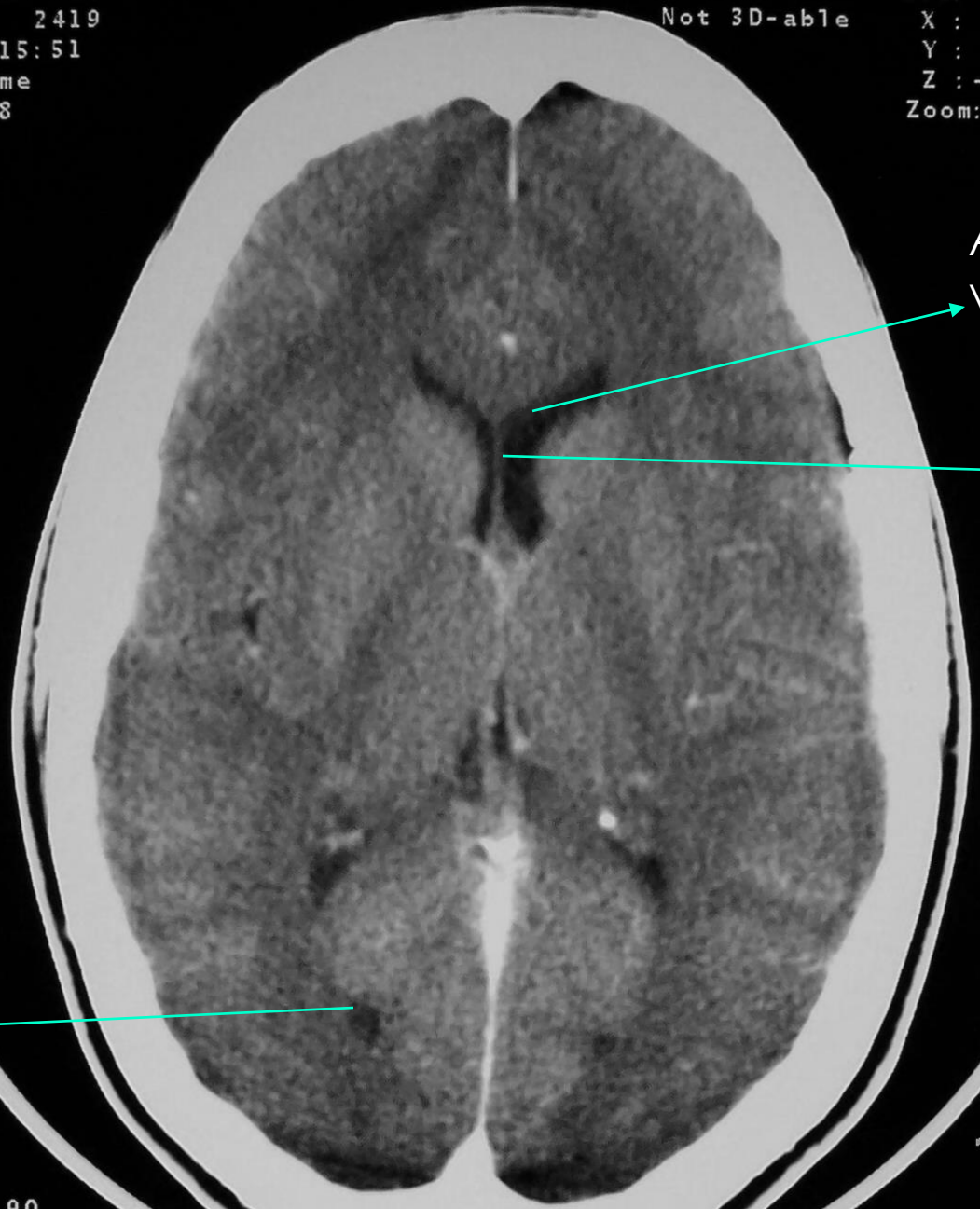Ant horn lat vent

Sept pellucidum

Post horn lat vent

10/13

Window: 90
Level: 40
Map: Ramp



BETHESDA OAK HOSPITAL
PQ2000 2419
28-Nov-95 15:51
Patient Name
ID: 0205468
CONT: C+

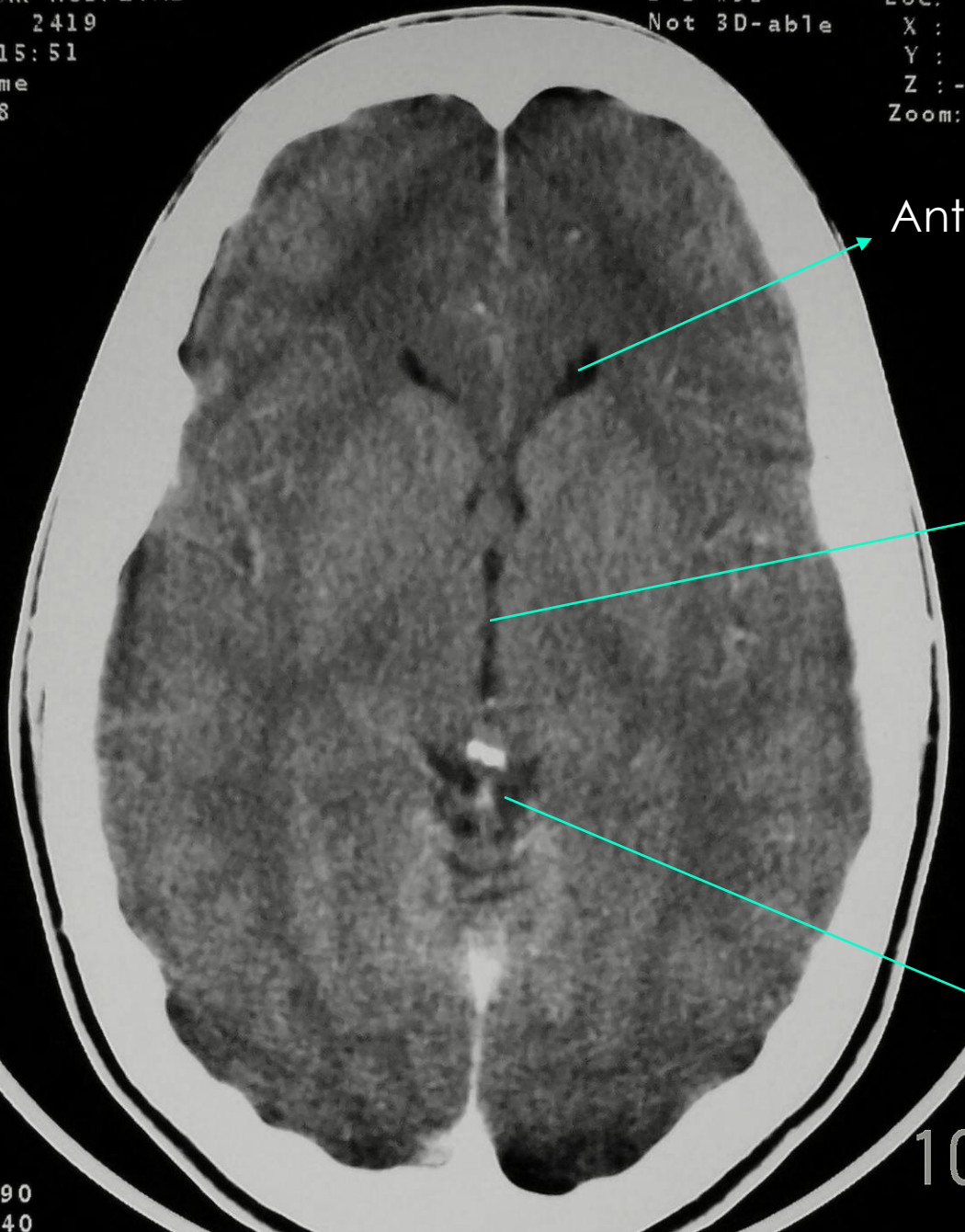ANT

2-D #32
Not 3D-able

Loc: 223 mm
X: -1.4 mm
Y: 11.1 mm
Z: -223.4 mm
Zoom: 2.07 X

R
G
T

L
F
T



Ant horn lat vent

3rd vent

Sup cist

Window: 90
Level: 40
Map: Ramp

10/13/

BETHESDA OAK HOSPITAL
PQ2000 2419
28-Nov-95 15:51
Patient Name
ID: 0205468
CONT: C+

ANT

2-D #31
Not 3D-able

Loc: 231 mm
X: -1.4 mm
Y: 11.1 mm
Z: -231.4 mm
Zoom: 2.07 X

Cist lat sulcus

3rd vent

Ambient cist

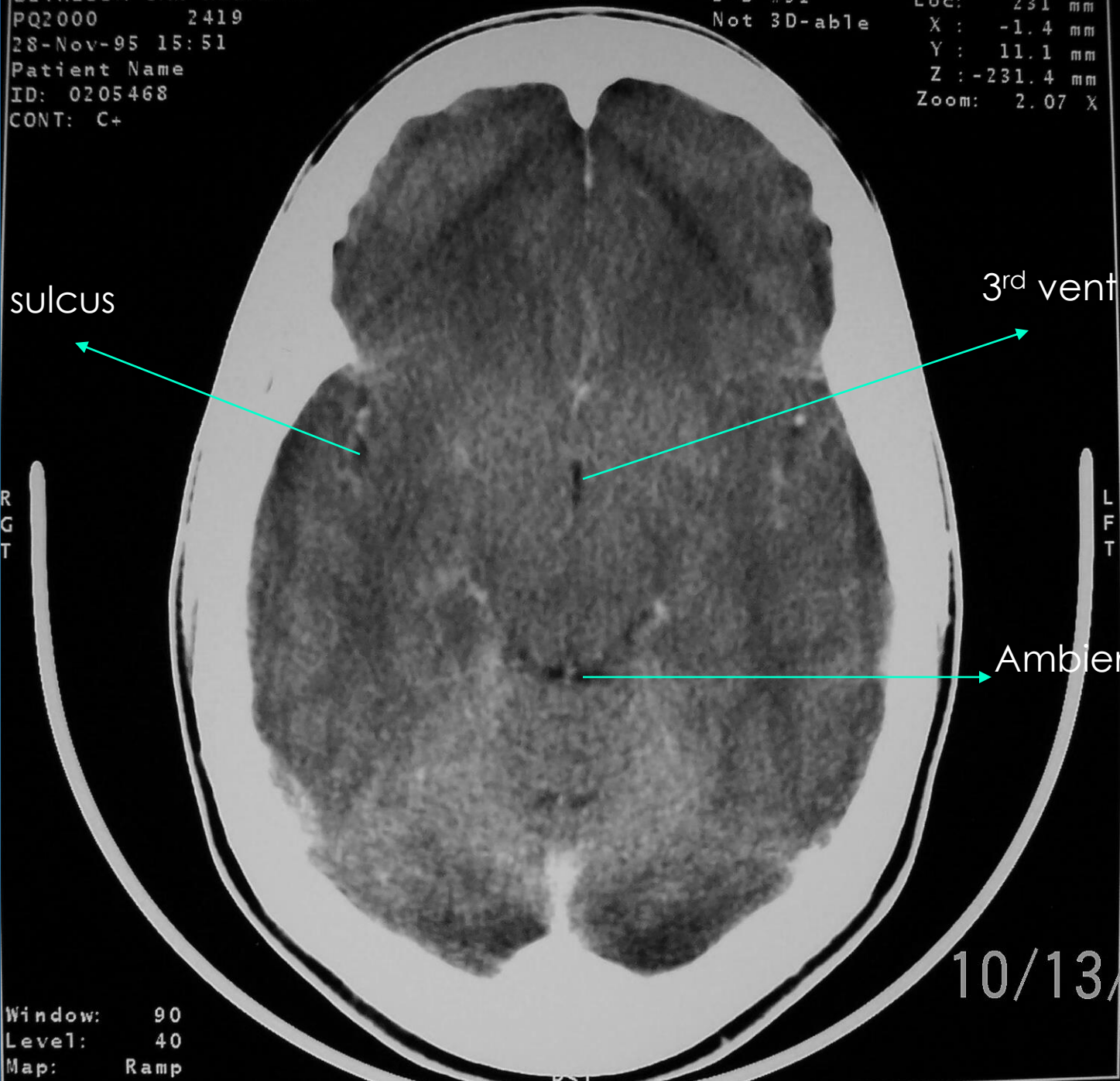
R
G
T

L
F
T

Window: 90
Level: 40
Map: Ramp

10/13/

PSI




BETHESDA OAK HOSPITAL
PQ2000 2419
28-Nov-95 15:51
Patient Name
ID: 0205468
CONT: C+

ANT

2-D #30
Not 3D-able

Loc: 239 mm
X: -1.4 mm
Y: 11.1 mm
Z: -239.5 mm
Zoom: 2.07 X

Suprasellar cist



Cerebral aqueduct



R
G
T

L
F
T

Window: 90
Level: 40
Map: Ramp

PST

10/13/

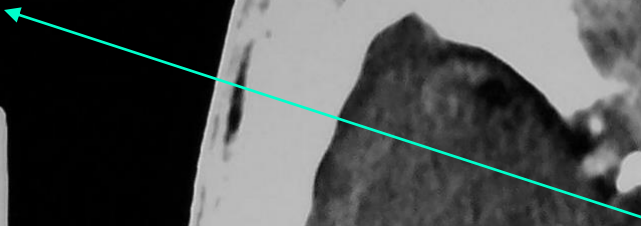
BETHESDA OAK HOSPITAL
PQ2000 2419
28-Nov-95 15:51
Patient Name
ID: 0205468
CONT: C+

ANT


2-D #29
Not 3D-able

Loc: 244 mm
X: -1.4 mm
Y: 11.1 mm
Z: -244.5 mm
Zoom: 2.07 X

Pontine cist



4th vent



R
G
T

L
F
T

10/1

Window: 108
Level: 37
Map: Ramp

BETHESDA OAK HOSPITAL
PQ2000 2419
28-Nov-95 15:51
Patient Name
ID: 0205468
CONT: C+

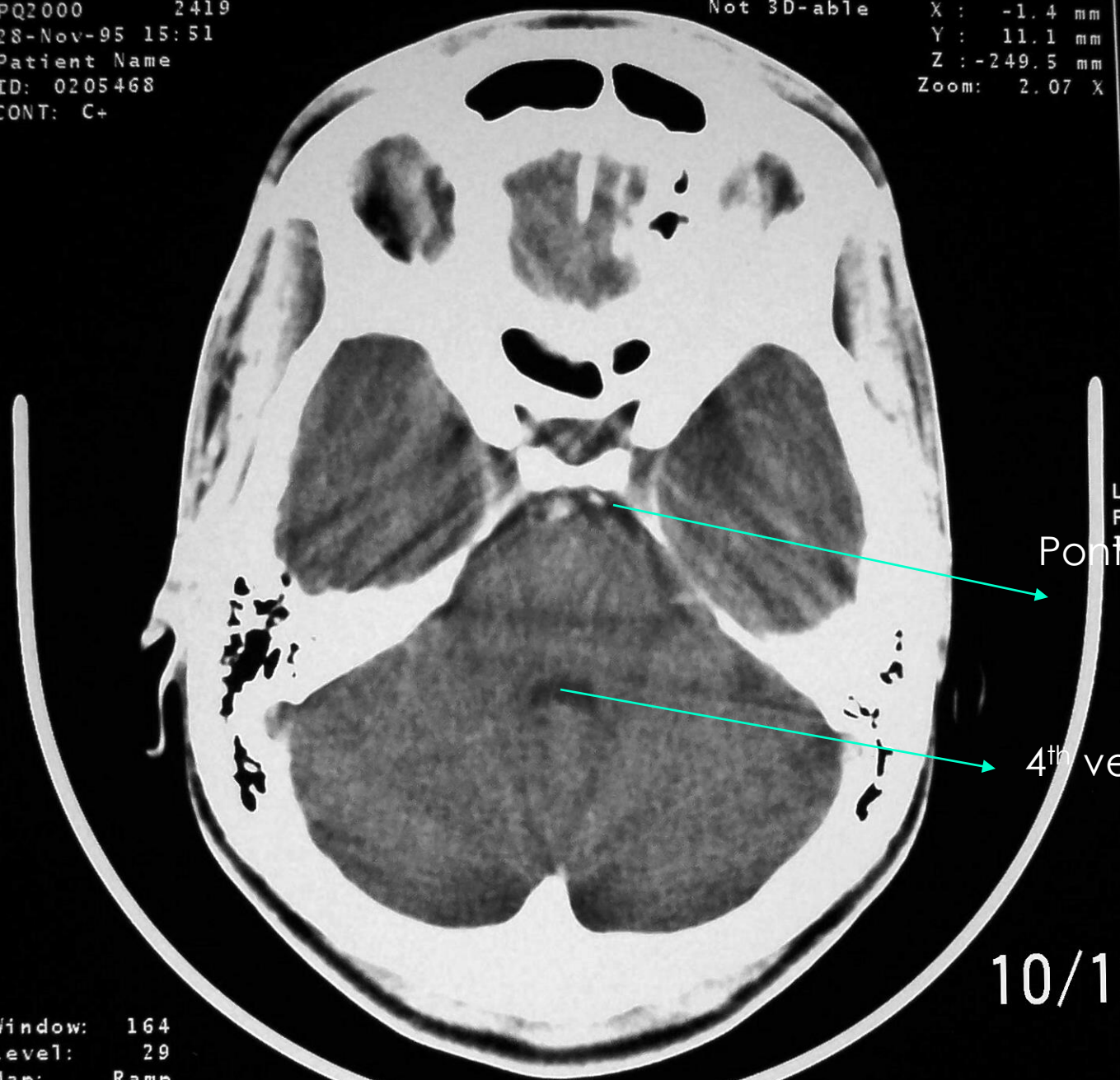
ANT

2-D #28
Not 3D-able

Loc: 249 mm
X: -1.4 mm
Y: 11.1 mm
Z: -249.5 mm
Zoom: 2.07 X

R
G
T

L
F



Pontine cist

4th vent

10/15

Window: 164
Level: 29
Map: Ramp

PST

BETHESDA OAK HOSPITAL
PQ2000 2419
28-Nov-95 15:51
Patient Name
ID: 0205468
CONT: C+

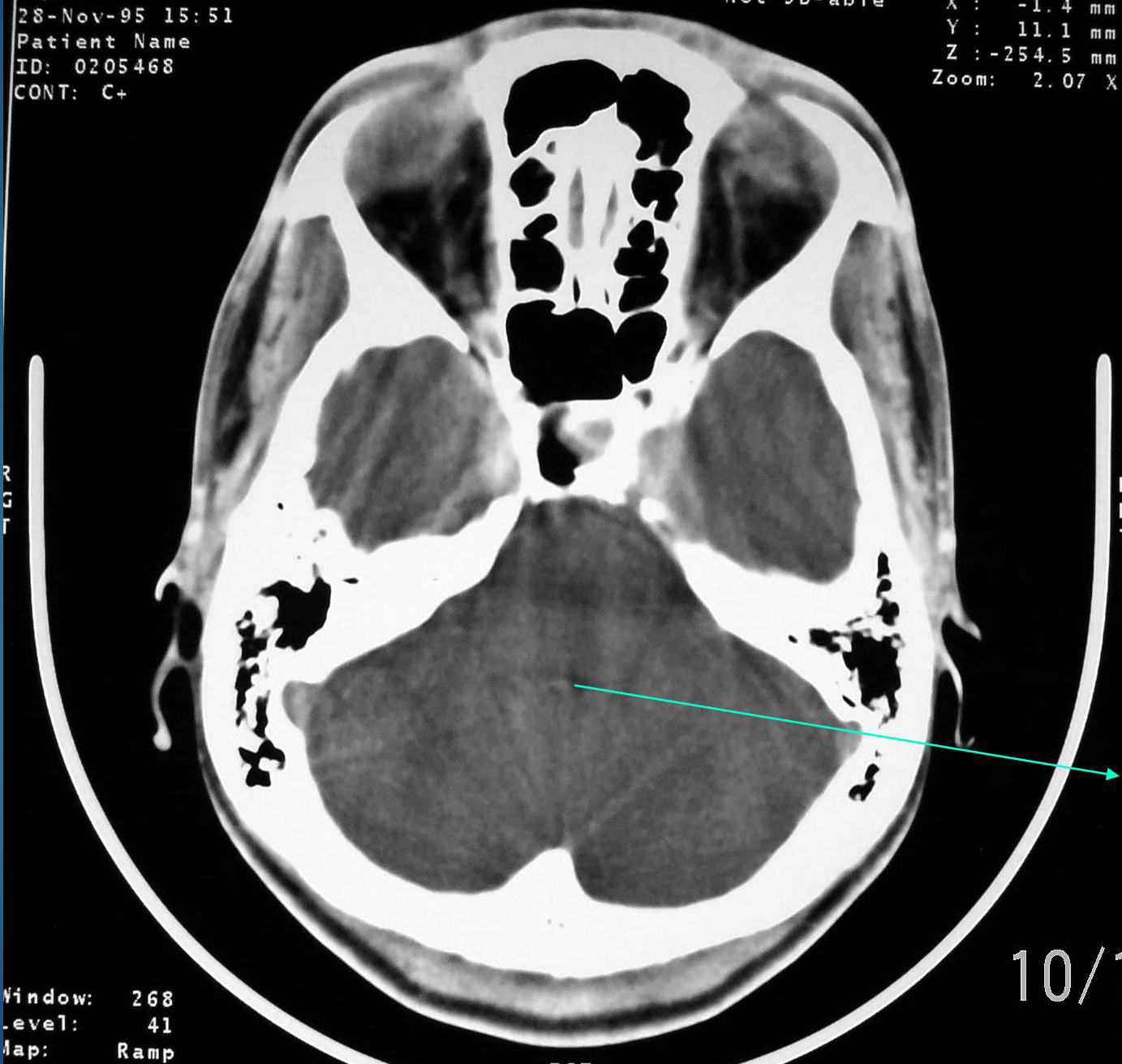
ANT

2-D #27
Not 3D-able

Loc: 254 mm
X: -1.4 mm
Y: 11.1 mm
Z: -254.5 mm
Zoom: 2.07 X

R
L
T

L
F
T



4th vent

10/1

Window: 268
Level: 41
Map: Ramp

PST

Anatomy of the Neck

Patient Name
ID: 0922774
CONT: C+

T : 0.0 mm
Z : -545.1 mm
Zoom: 1.60 X

MASSETER
MUSCLE

PAROTID GLAND

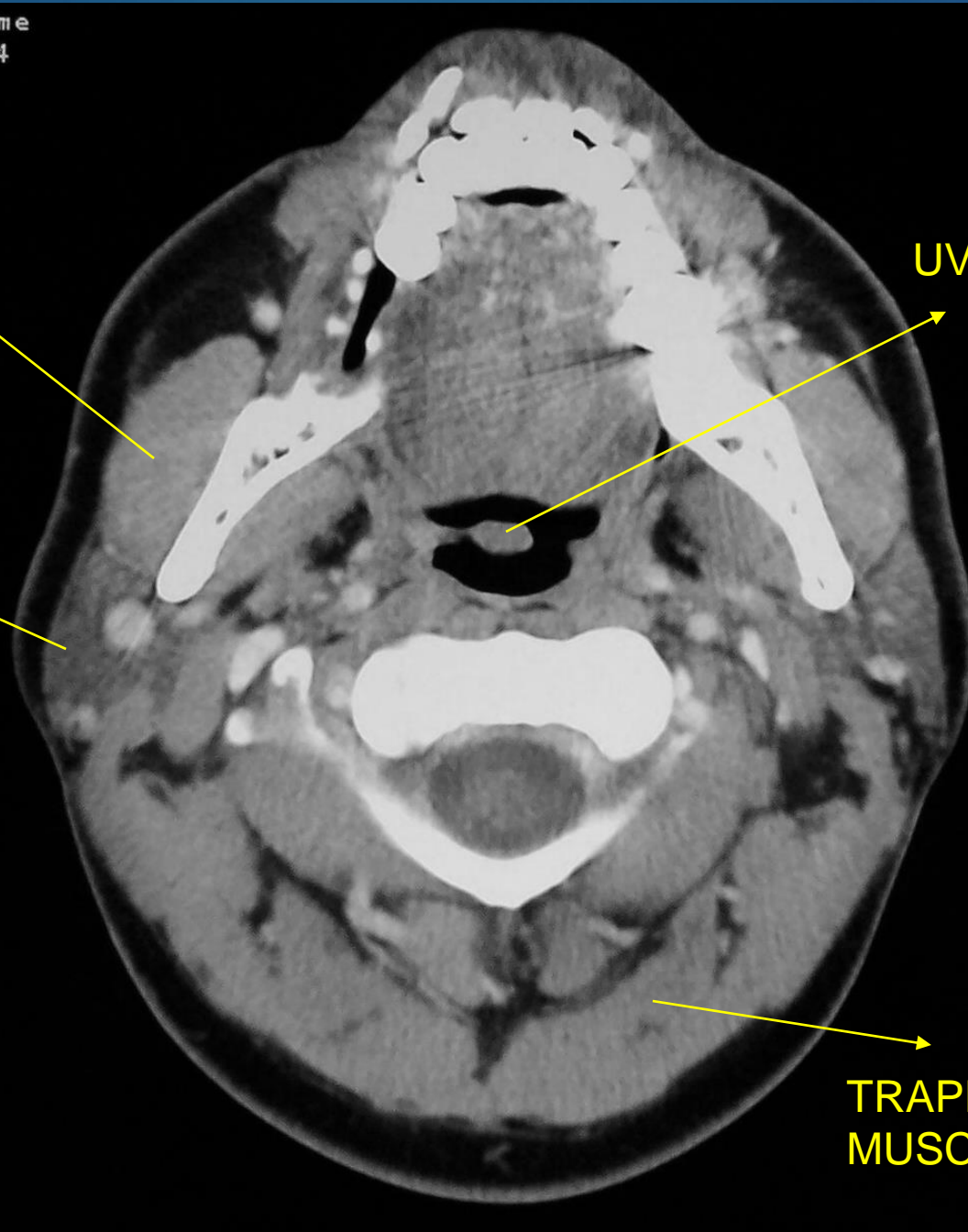
UVULA

L
F
T

11 cm

TRAPEZIUS
MUSCLE

10



CONT: C+

Z : -572.1 mm
Zoom: 1.60 X

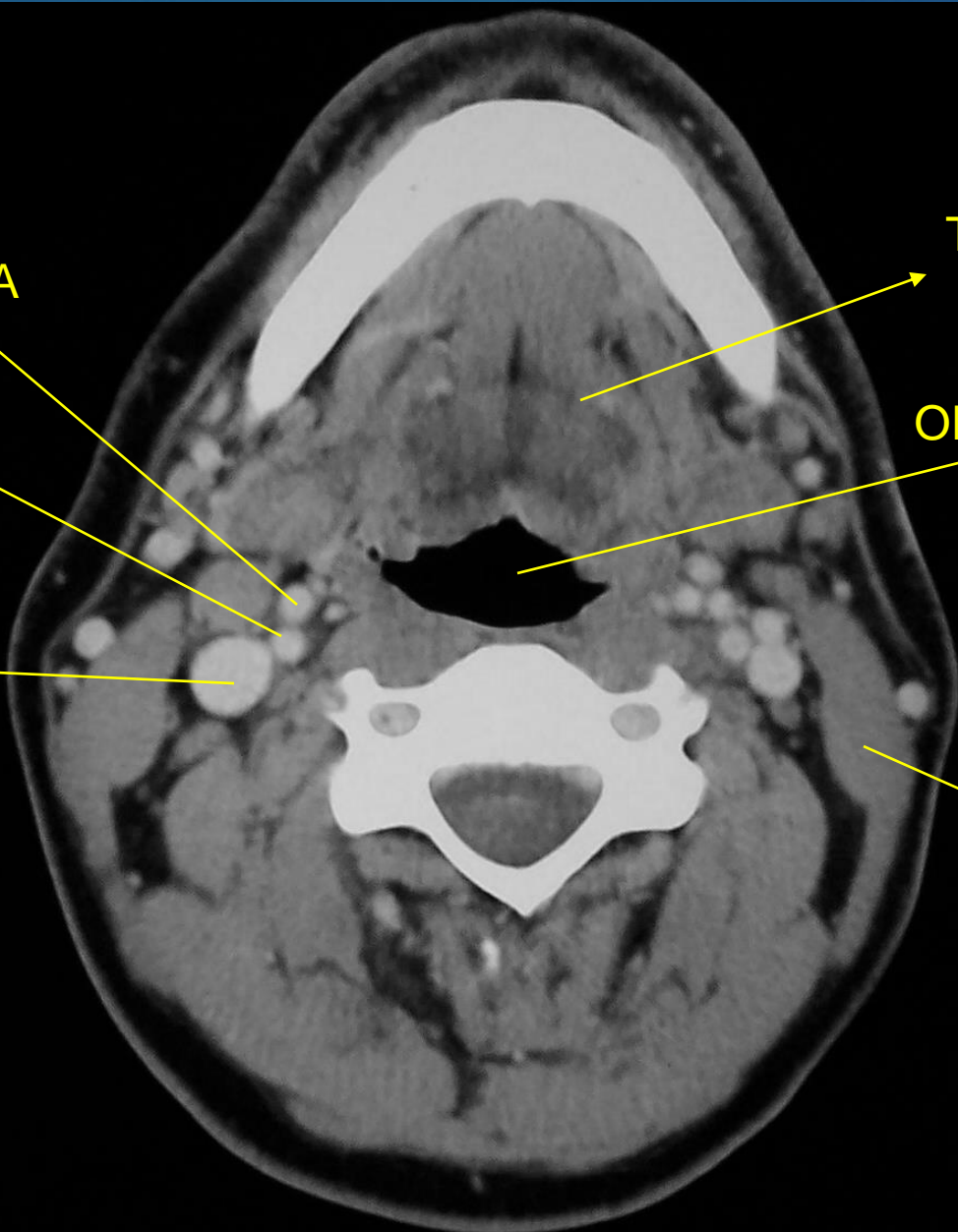
11 cm

ECA
ICA
IJV
TONGUE
OROPHARYNX
SCM MUSCLE

L
F
T

Window: 400

10/27



ID: 0922774
CONT: C+

Z : -578.2 mm
Zoom: 1.60 X

SOM MUSCLE



LAMINA



ERECTOR SPINAE MUSCLE



11 cm

L
F
T

CONT: C+

VALLECULAE

Zoom: 1.60 X

PLATYSMA
MUSCLE

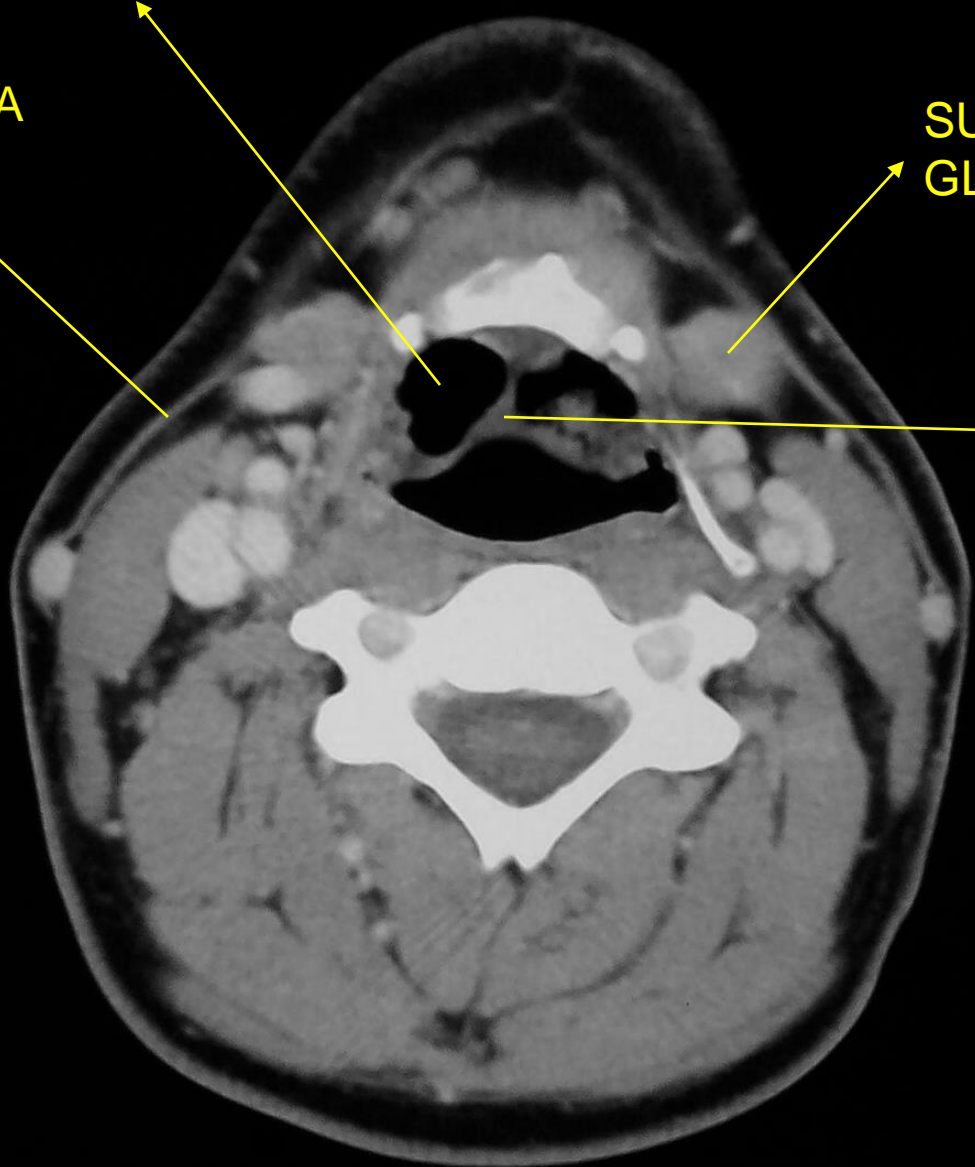
SUBMANDIBULAR
GLAND

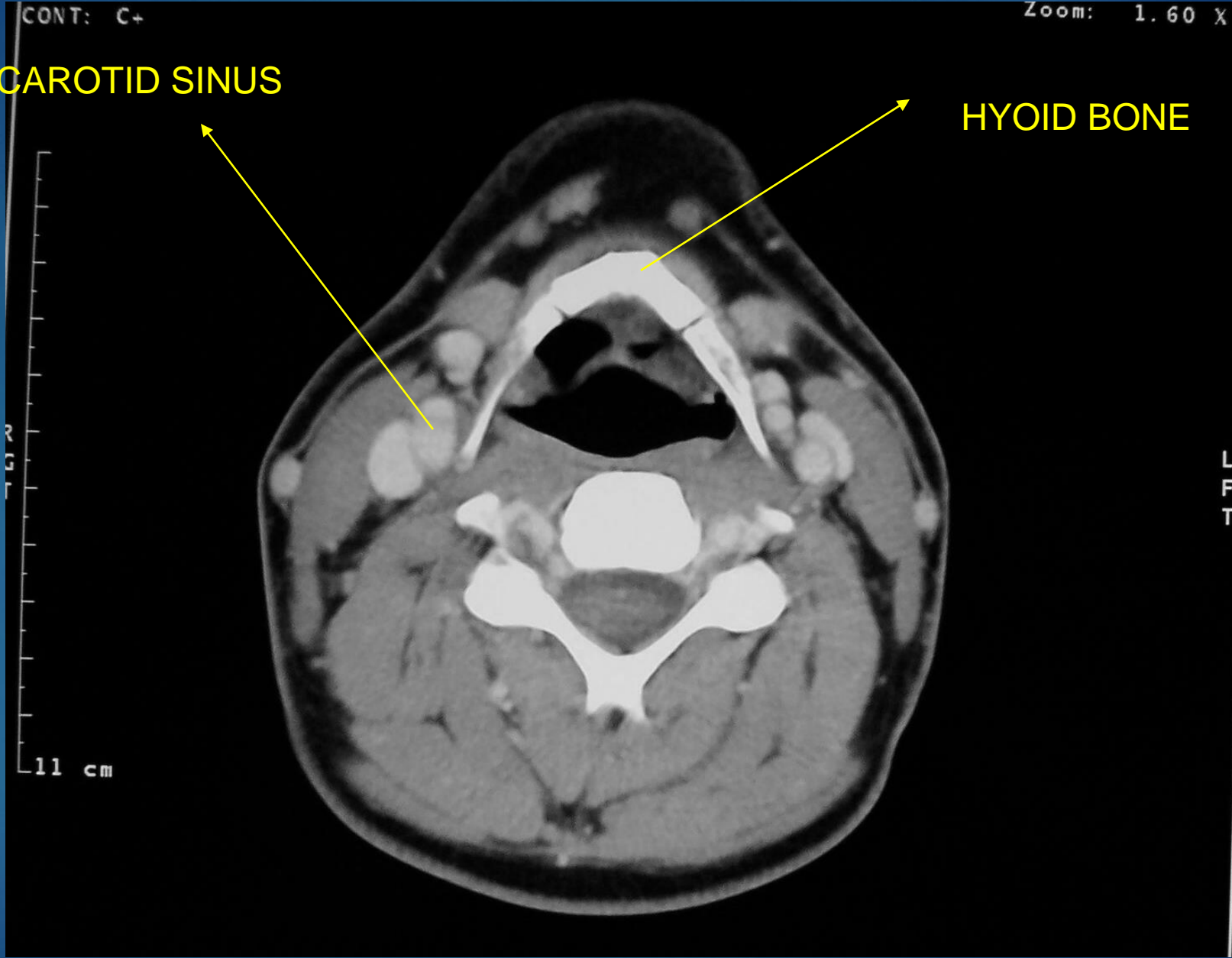
EPIGLOTTIS

R
C
T

L
F
T

11 cm





CAROTID SINUS

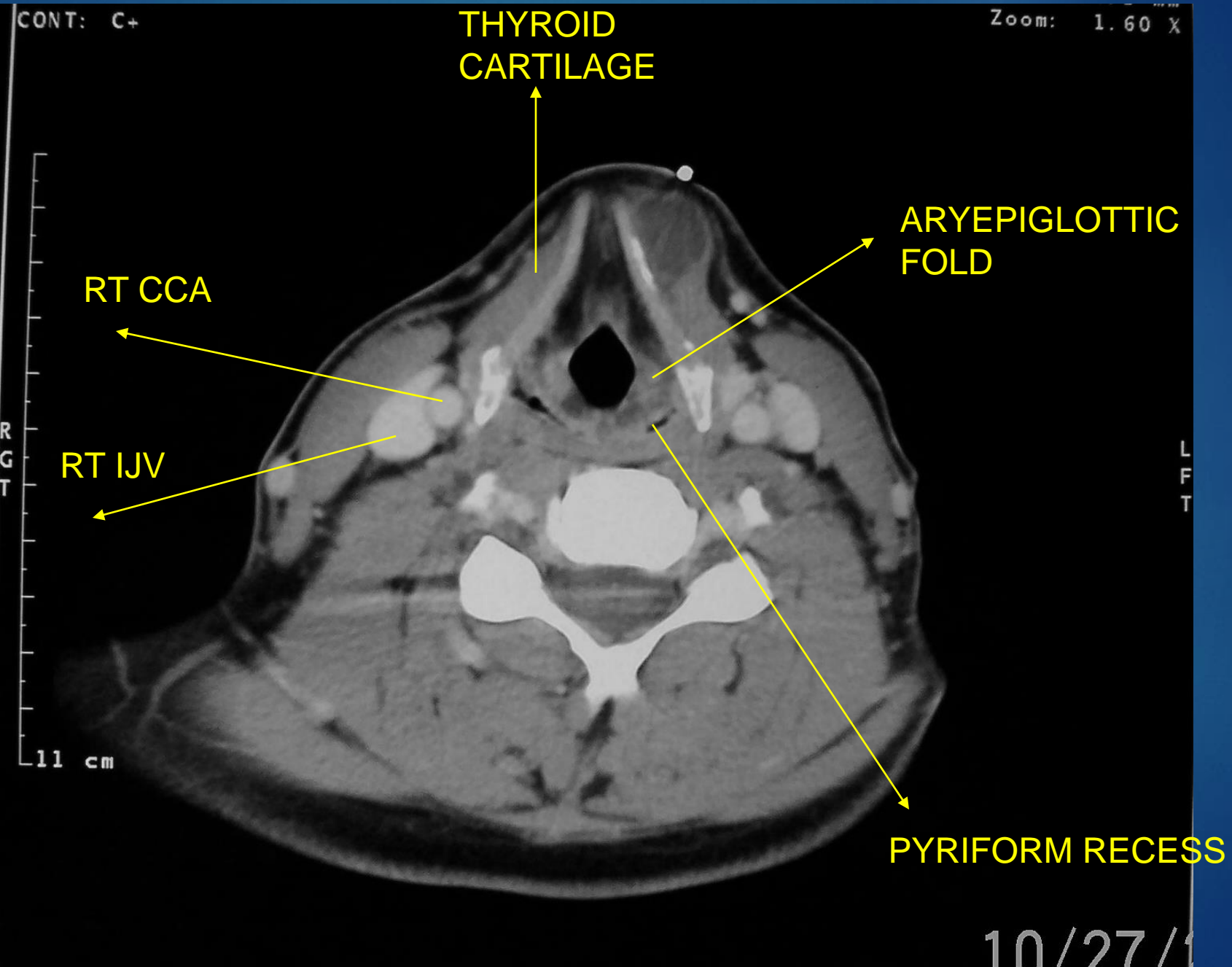
HYOID BONE

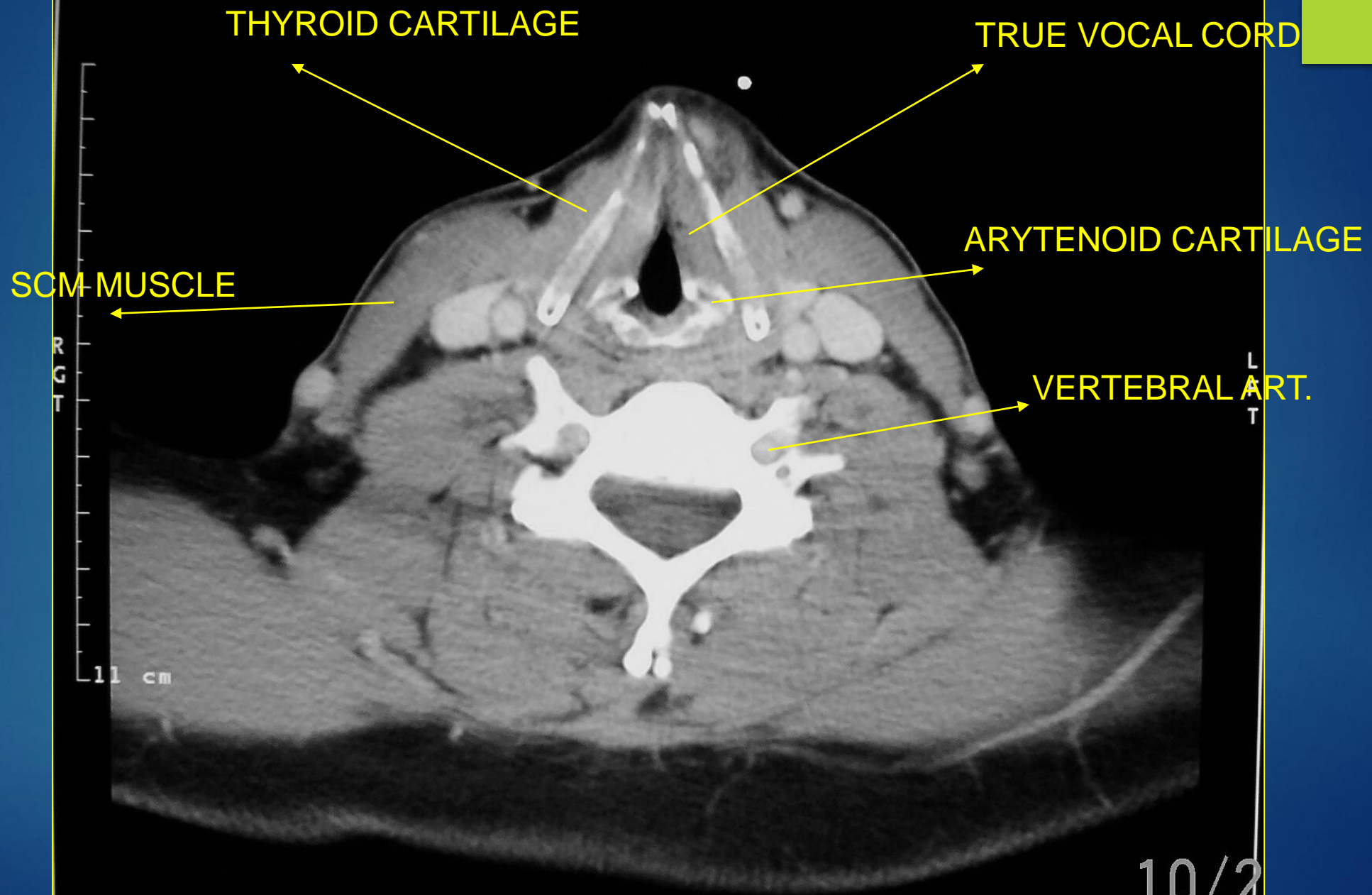
CONT: C+

Zoom: 1.60 X

11 cm

L
F
T





CONT: C+

Zoom: 1.60 X

CRICOID CARTILAGE

THYROID CARTILAGE

R
G
T

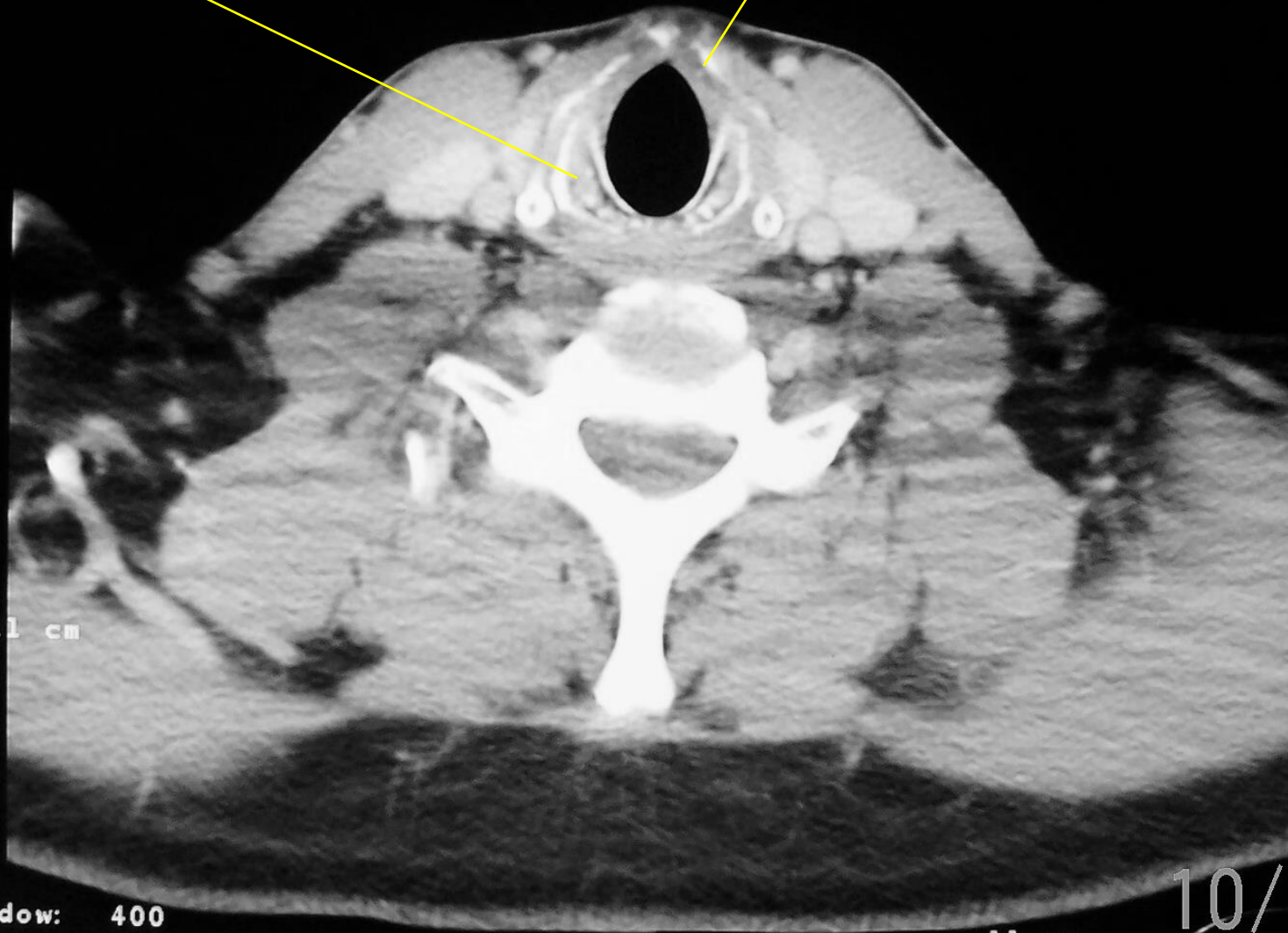L
F
T

11 cm

Window: 400
Level: 20

11 cm

10/27



CONT: C+

Zoom: 1.60 X

THYROID GLAND

LT CCA

LT IJV

R
G
T

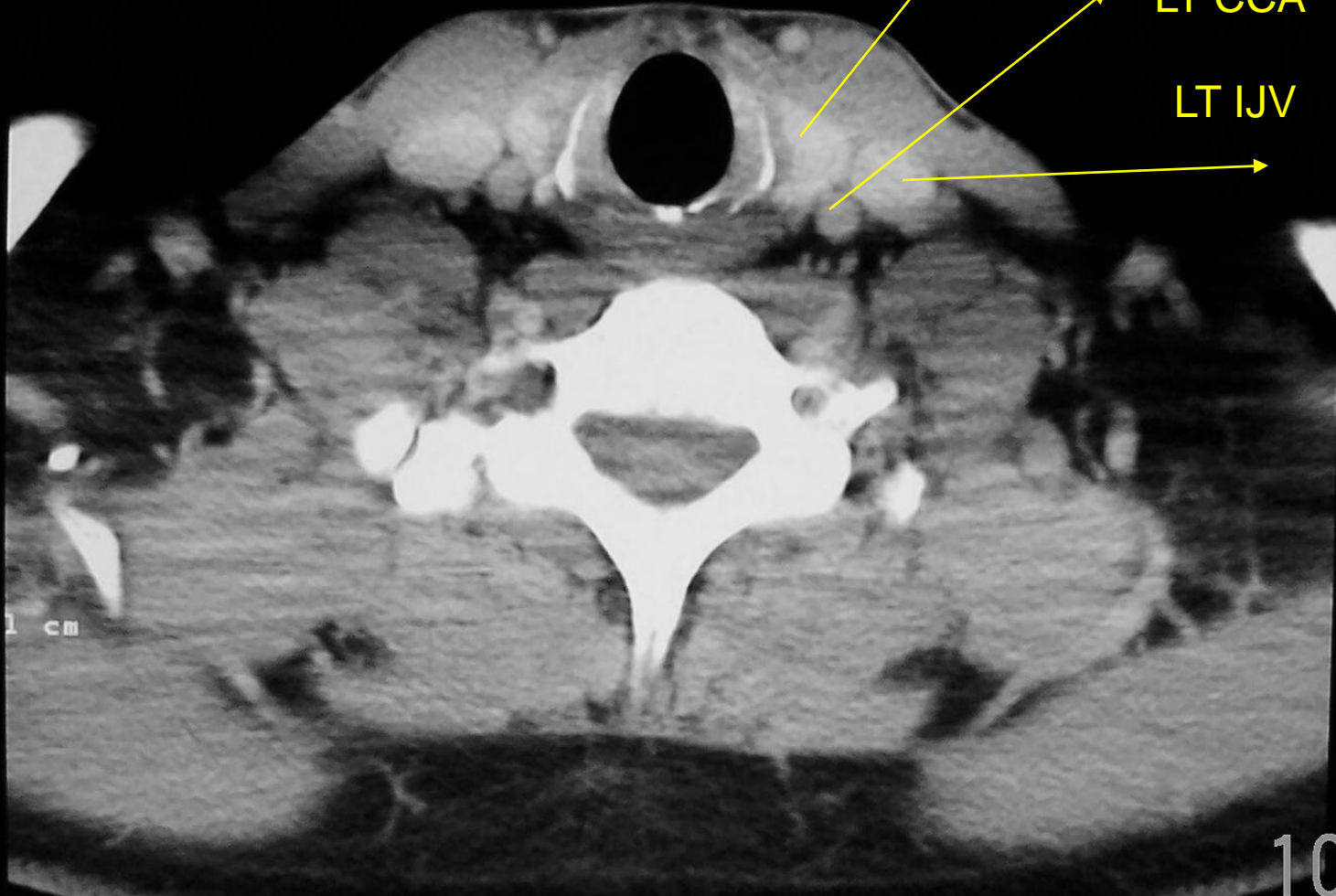
L
F
T

11 cm

11 cm

Window: 400
Level: 20

10/2



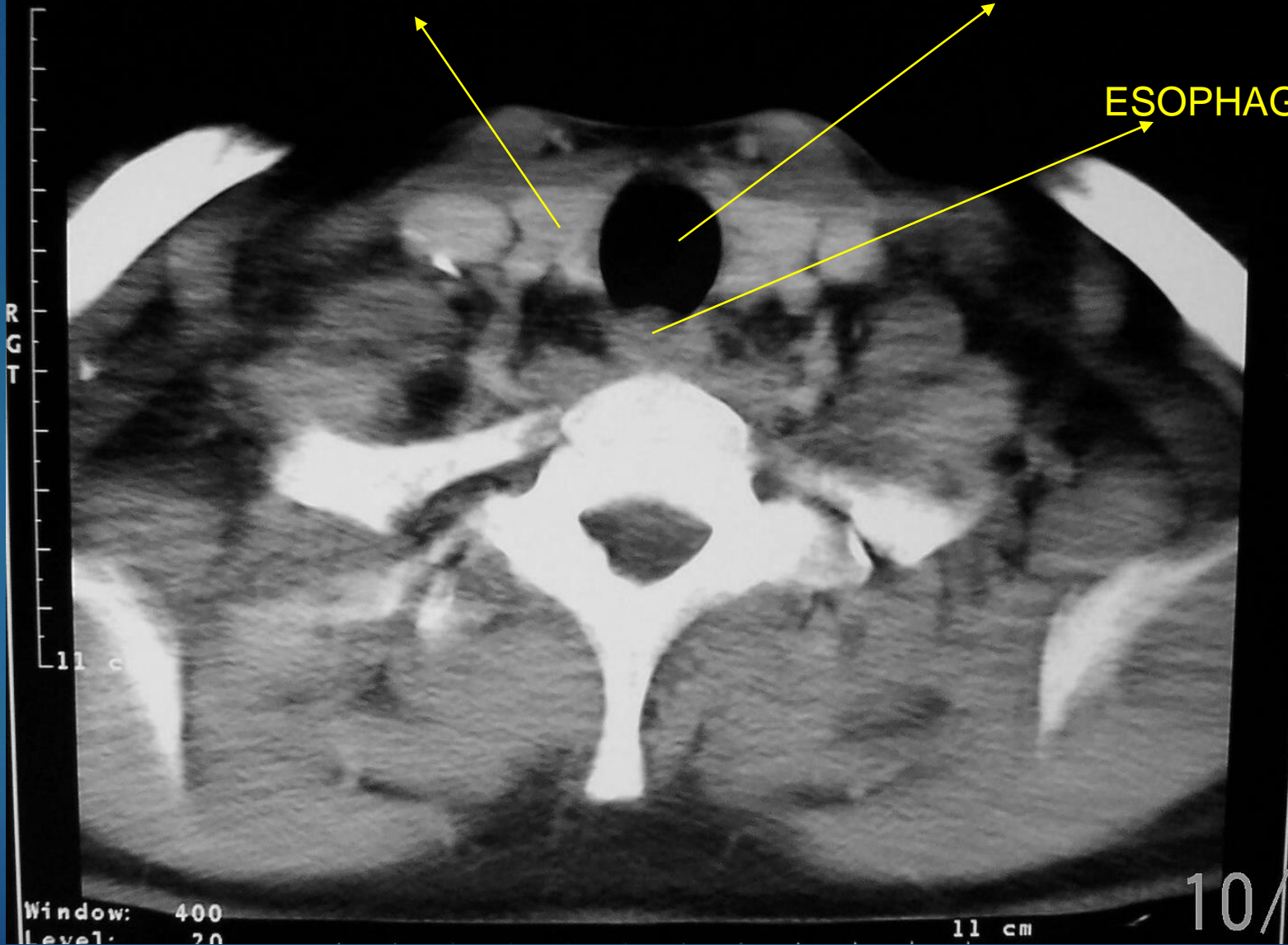
CONT: C+

ZOOM: 1.60

THYROID GLAND

TRACHEA

ESOPHAGUS



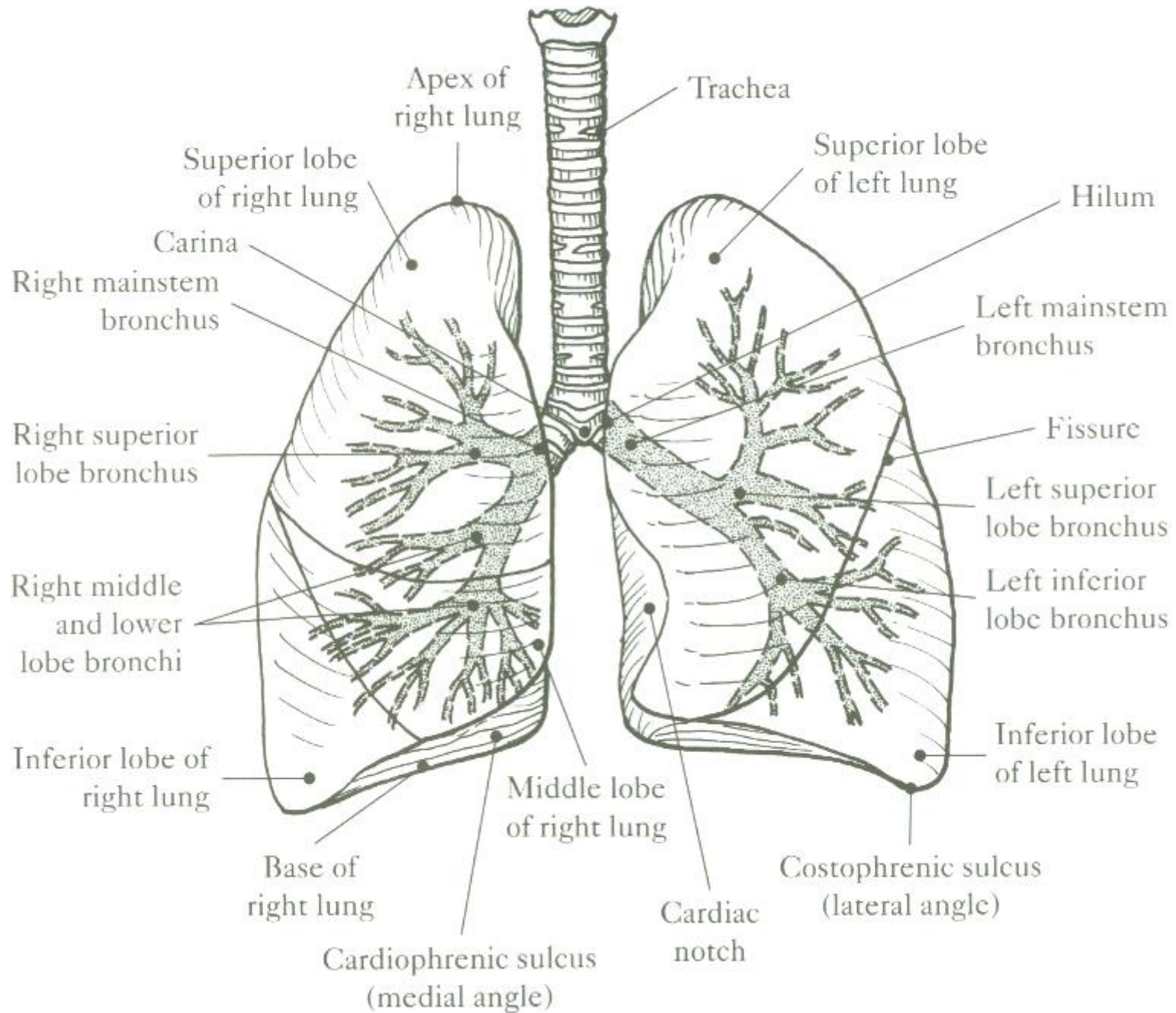
Window: 400
Level: 20

11 cm

10/



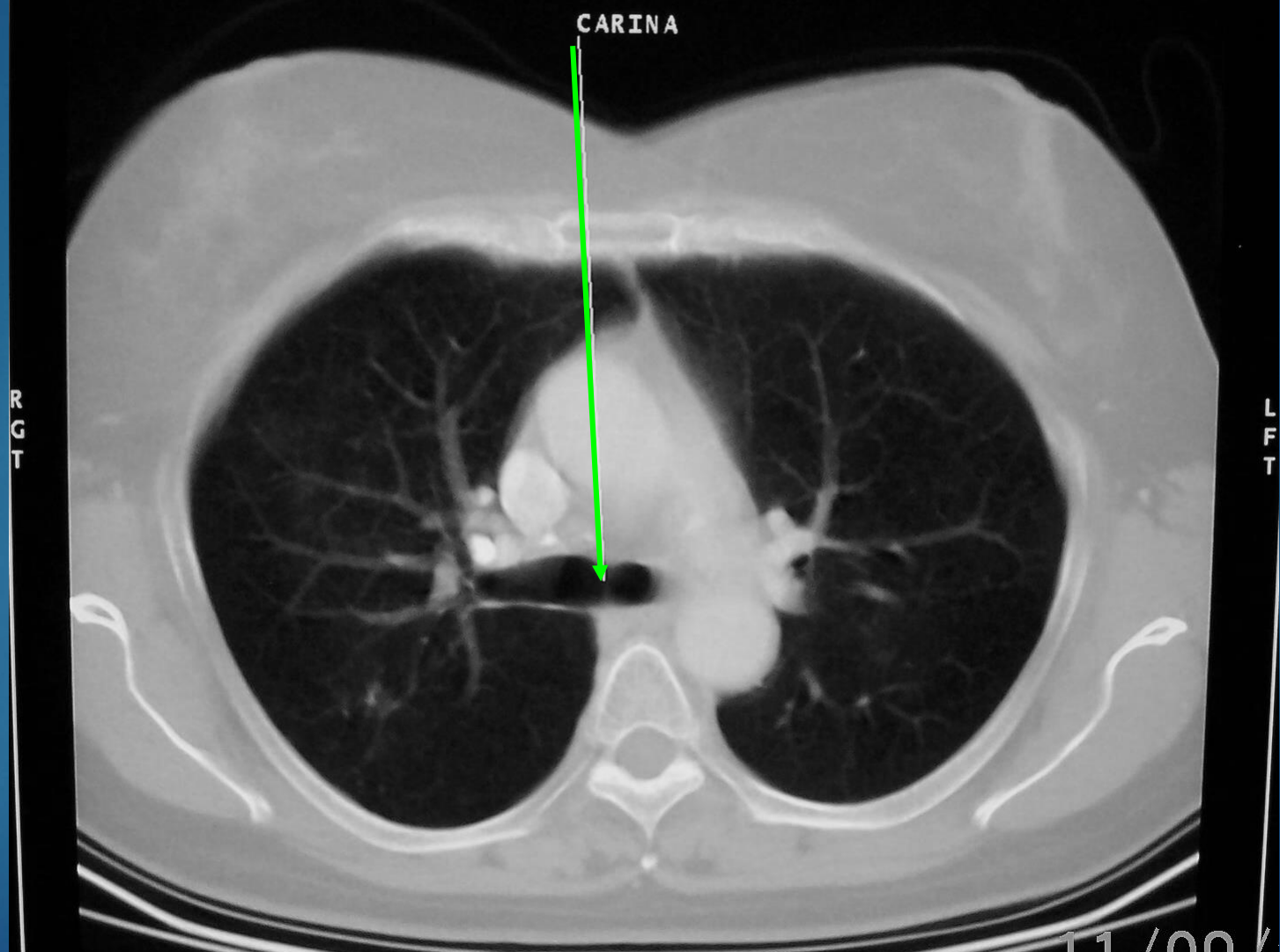
Anatomy of the Thorax



BETHESDA OAK HOSPITAL
PQ2000 3317
07-Mar-96 09:41
Patient Name
ID: 1150472
CONT: C+

ANT 2-D #12
Active

Loc: 861 mm
X : 1.1 mm
Y : -3.0 mm
Z : -861.88mm
Zoom: 1.60 X



Window: 1600
Level: -300
Map: Ramp

11/09/

PST

BETHESDA OAK HOSPITAL
PQ2000 3317
07-Mar-96 09:41
Patient Name
ID: 1150472
CONT: C+

ANT

2-D #13
Active

Loc: 871 mm
X: 1.1 mm
Y: -3.0 mm
Z: -871.88mm
Zoom: 1.60 X

RT. MAIN BRONCHUS

LT. MAIN BRONCHUS

R
G
T

L
F
T

Window: 1634
Level: -535
Map: Ramp

PST

11/09/

BETHESDA OAK HOSPITAL
PQ5000 4973
23-Aug-96 10:25
Patient Name
ID: 1490672
CONT: C+

ANT

2-D #34
Active

Loc: 1101 mm
X : 0.0 mm
Y : 0.0 mm
Z : -1101.7 mm
Zoom: 1.60 X

SEGMENTAL BRONCHUS

R
G
T

L
F
T

Window: 2000
Level: -400
Map: Ramp

PST

11/0

BETHESDA HOSPITAL
PQCT 32469
19-Mar-2000 13:46
Patient Name
ID: 1342897
CONT: C+

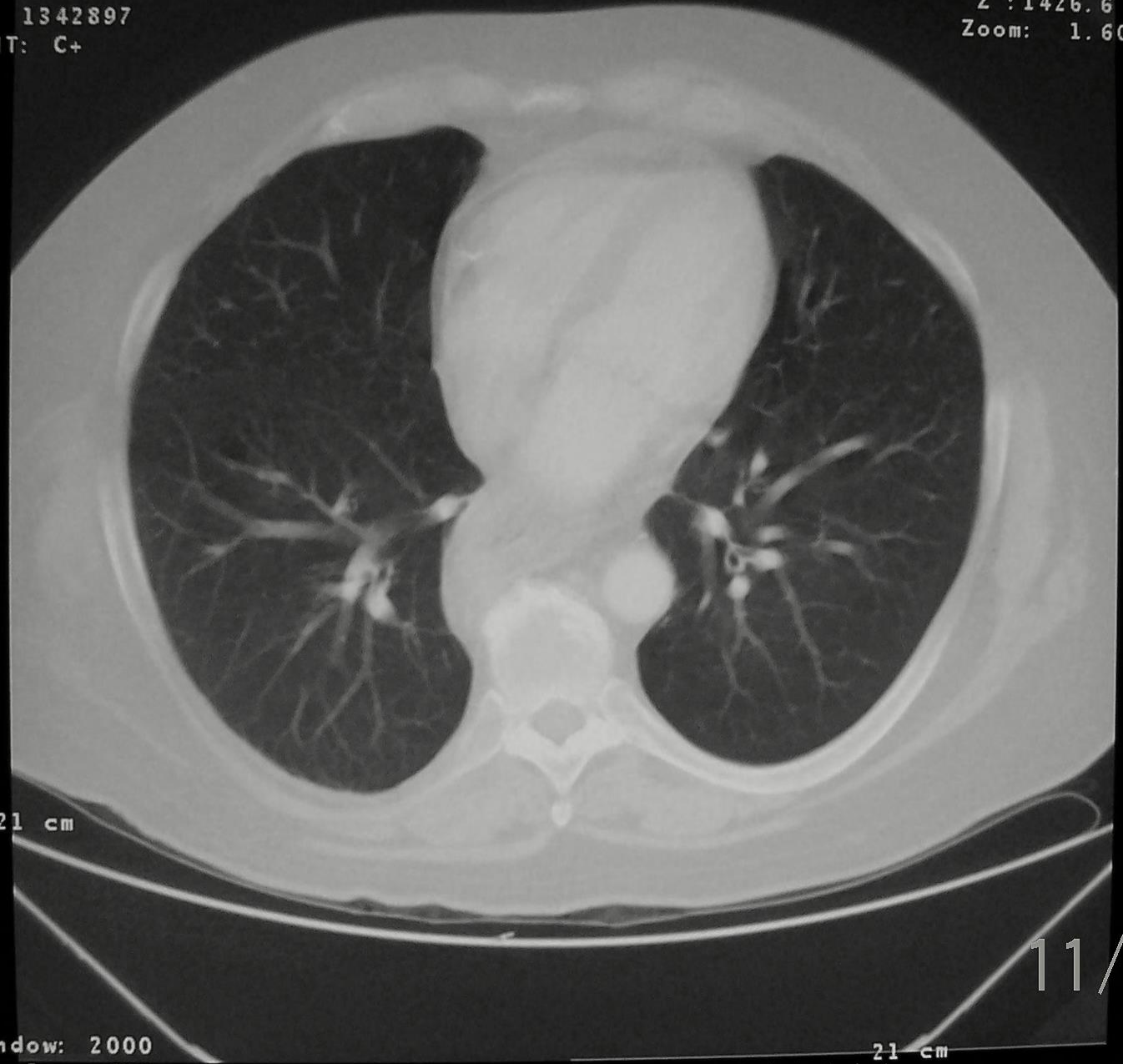
ANT

2-D #24
Active

Loc: 1426 mm
X : 0.0 mm
Y : 0.0 mm
Z : 1426.6 mm
Zoom: 1.60 X

R
T
C
M
21 cm

L
F
T



11/09

Window: 2000
Level: -650

21 cm

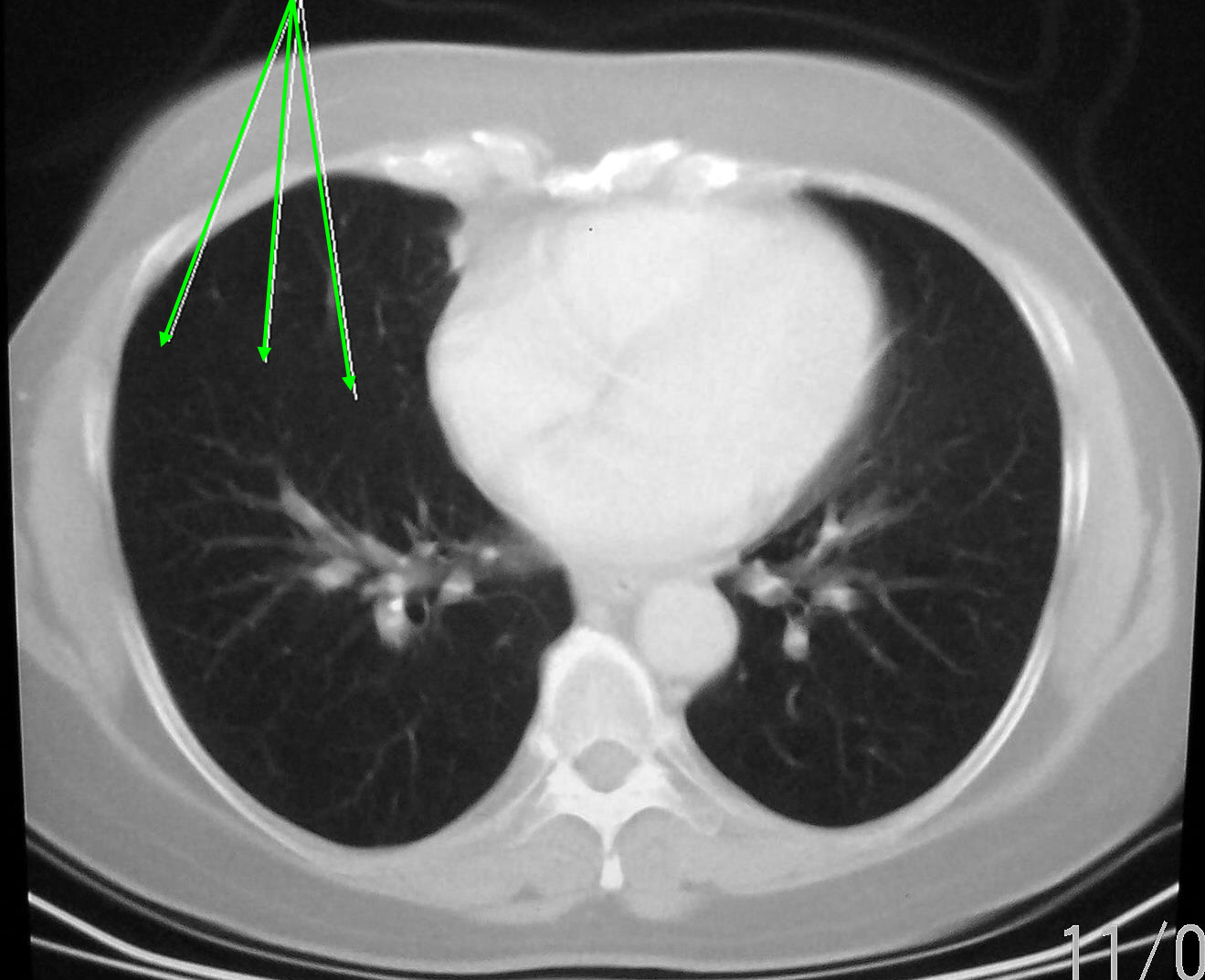
WETTESDA OAK HOSPITAL
Q2000 3317
07-Mar-96 09:41
Patient Name
ID: 1150472
CONT: C+

ANT

2-D #19
Active

Loc: 931 mm
X : 1.1 mm
Y : -3.0 mm
Z : -931.78 mm
Zoom: 1.60 X

FISSURE



RIGHT

LEFT

11/09/

Window: 1634
Level: -535
Map: Ramp

PST

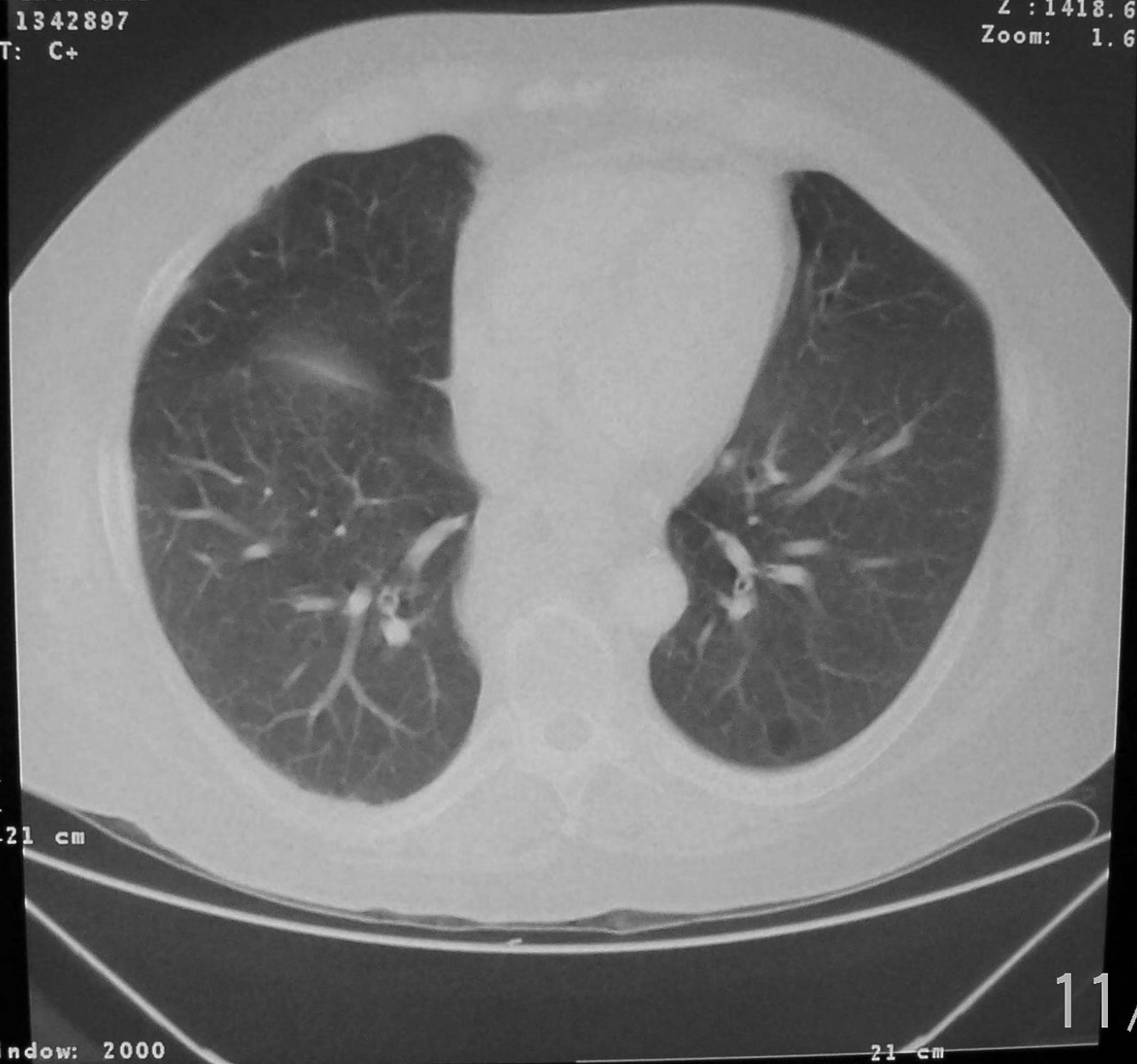
SETHESDA HOSPITAL
PQCT 32469
19-Mar-2000 13:46
Patient Name
ID: 1342897
CONT: C+

ANT 2-D #25
Active

Loc: 1418 mm
X : 0.0 mm
Y : 0.0 mm
Z : 1418.6 mm
Zoom: 1.60 X

R
G
T

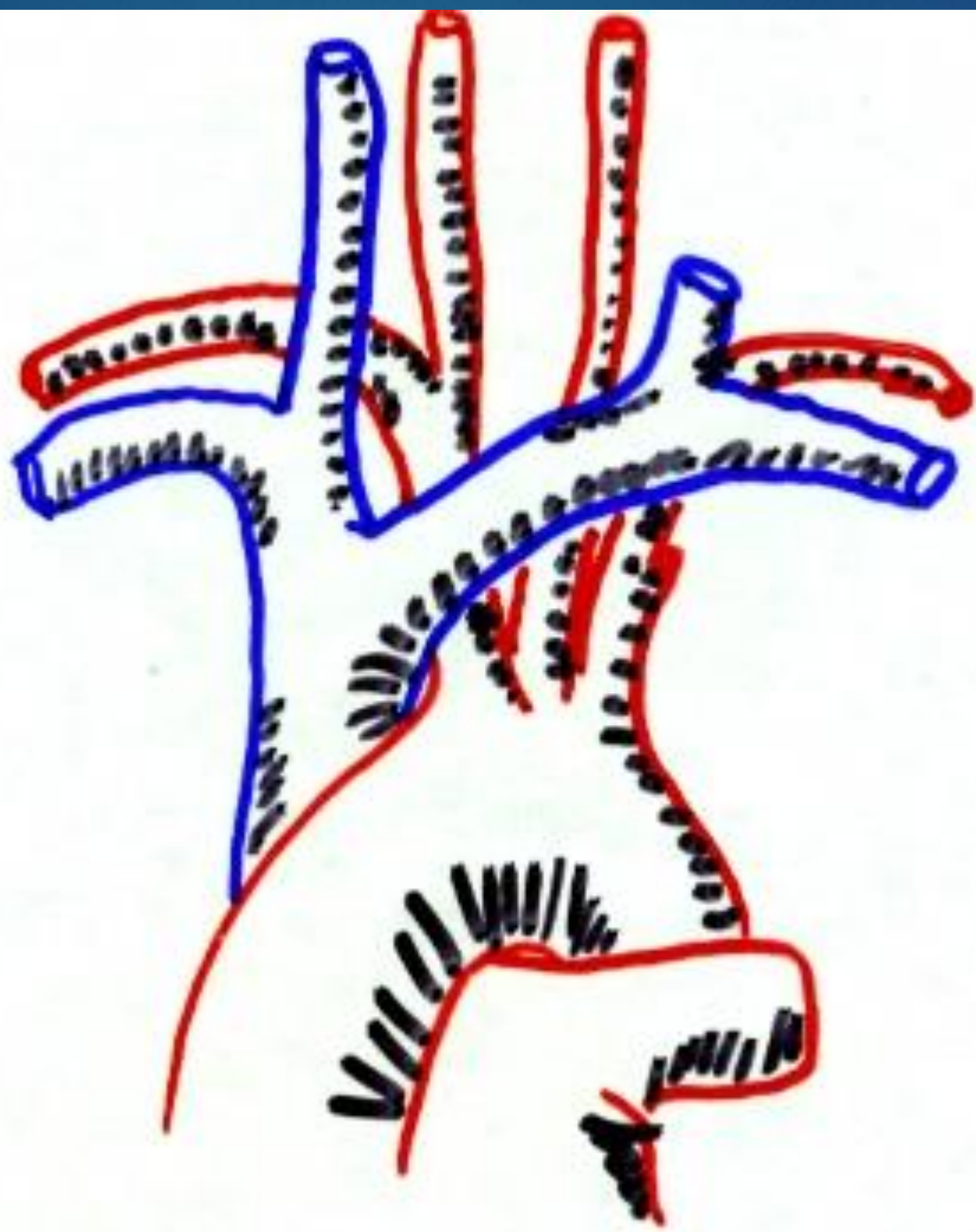
L
F
T

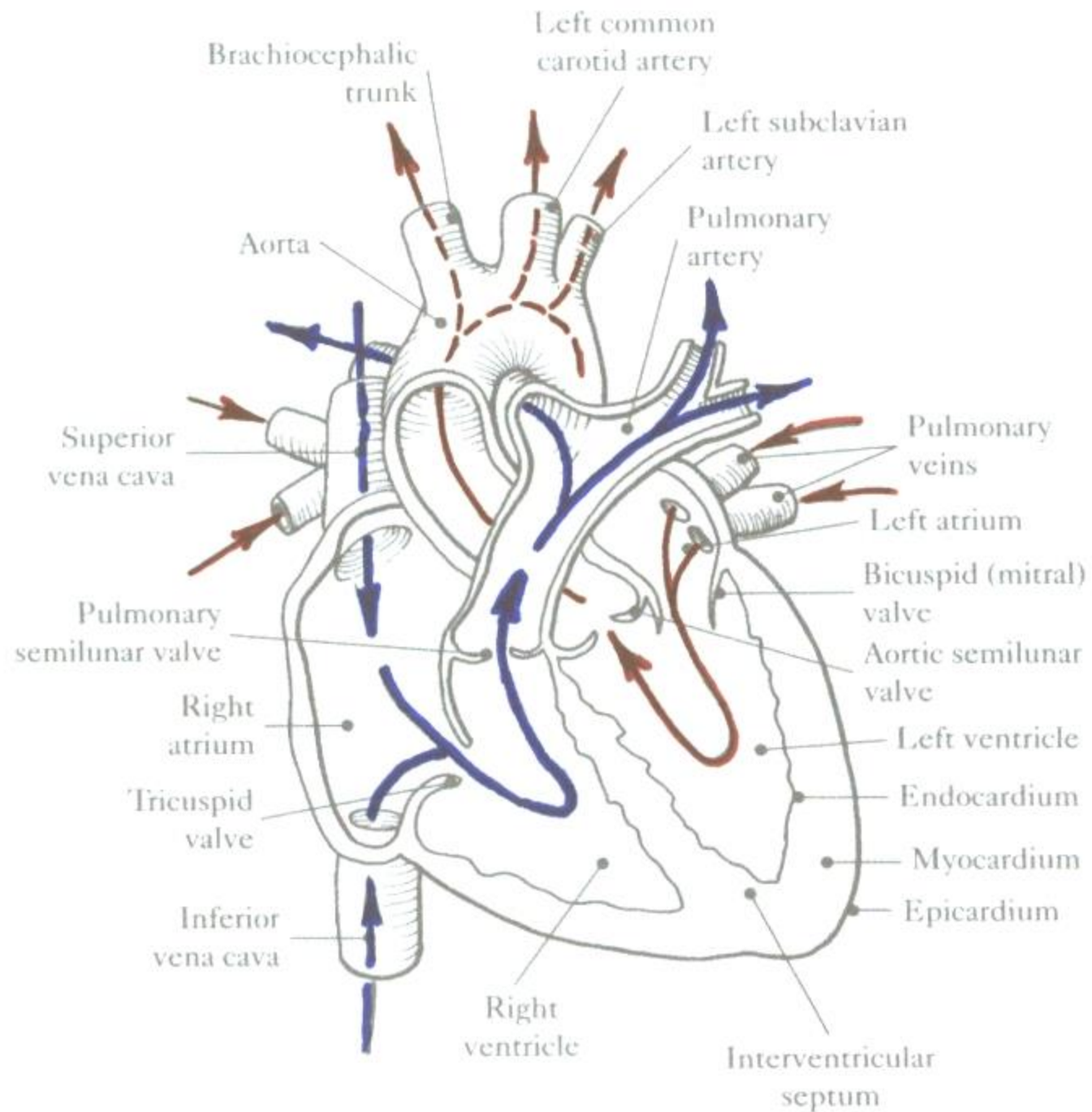


Window: 2000
Level: -650
Map: Ramp

PST

11/0





PQ2000 SS17
07-Mar-96 09:41
Patient Name
ID: 1150472
CONT: C+

Active

X : 1.1 mm
Y : -3.0 mm
Z : -771.7 mm
Zoom: 1.60 X

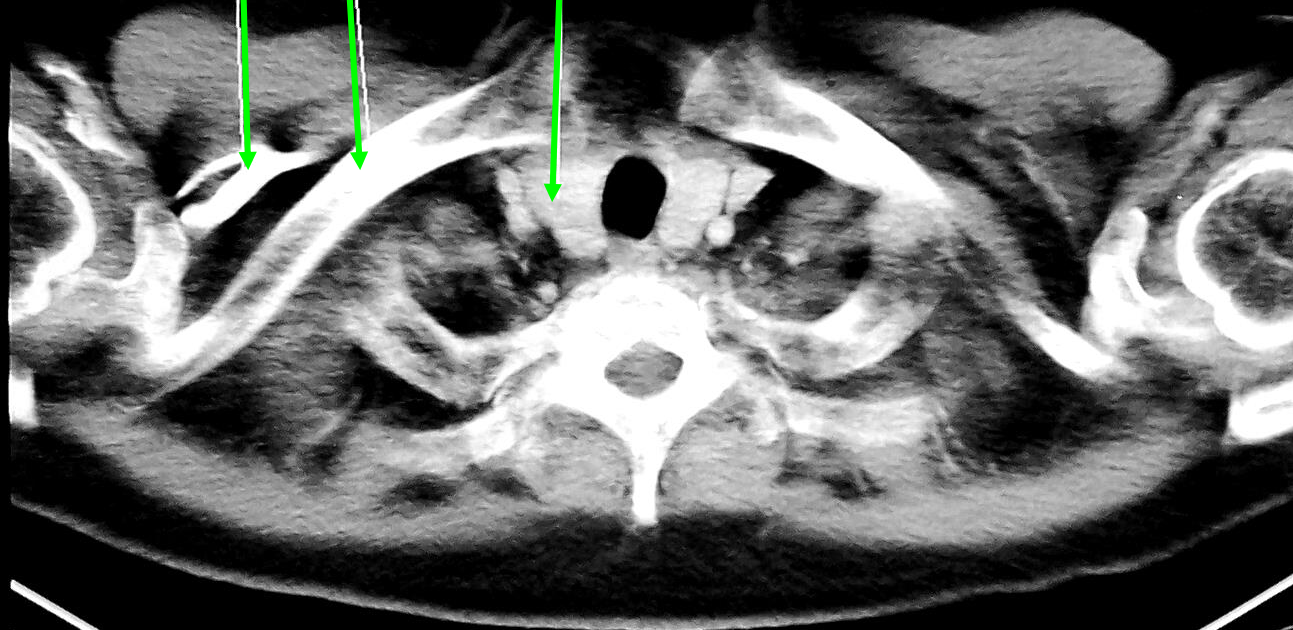
RT. SUBCLAVIAN VEIN

CLAVICLE

THYROID GLAND

R
G
T

L
F
T



Window: 387
Level: 31
Map: Ramp

PST

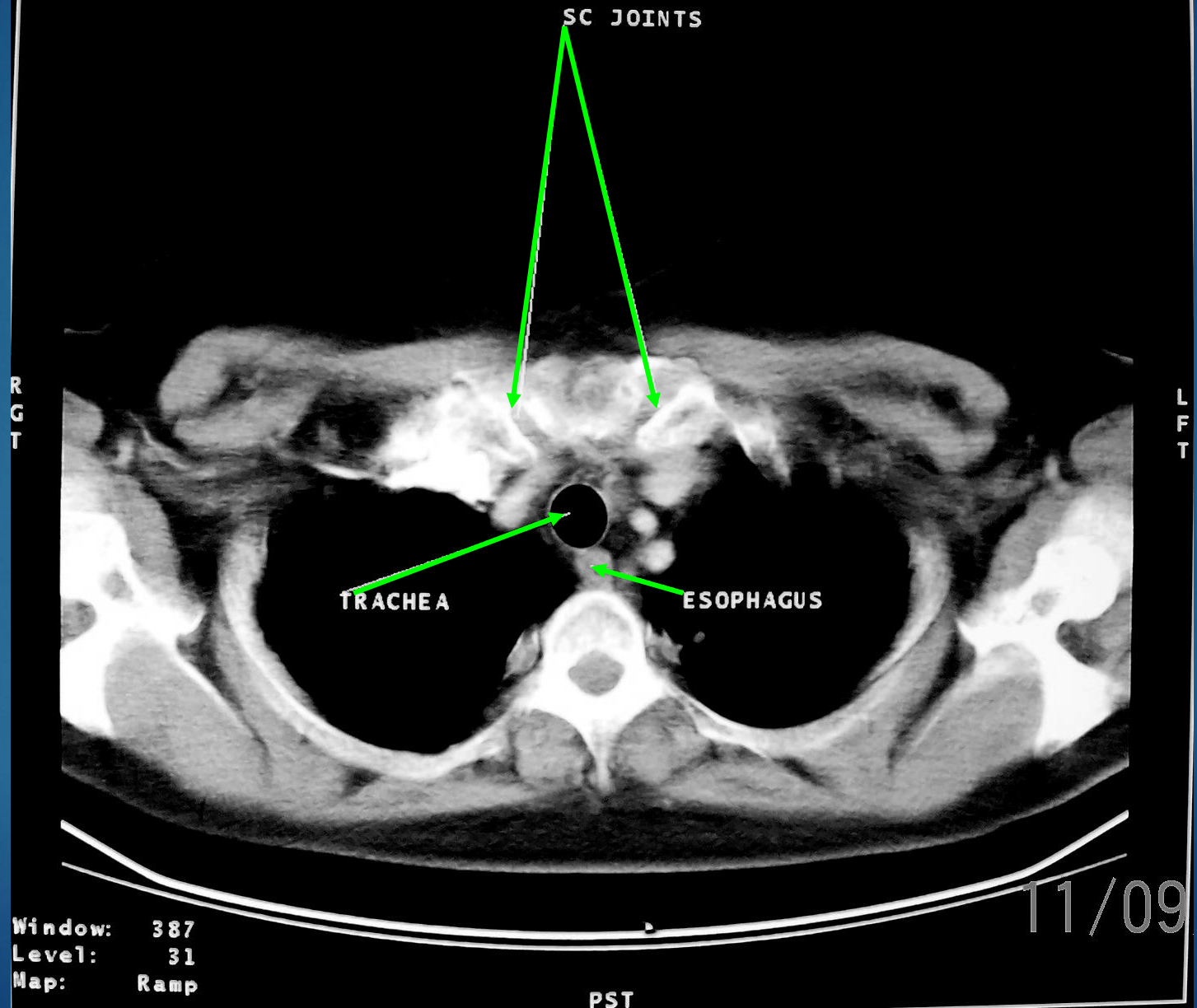
11/0

BETHESDA OAK HOSPITAL
PQ2000 3317
07-Mar-96 09:41
Patient Name
ID: 1150472
CONT: C+

ANT

2-D #5
Active

Loc: 791 mm
X : 1.1 mm
Y : -3.0 mm
Z : -791.7 mm
Zoom: 1.60 X

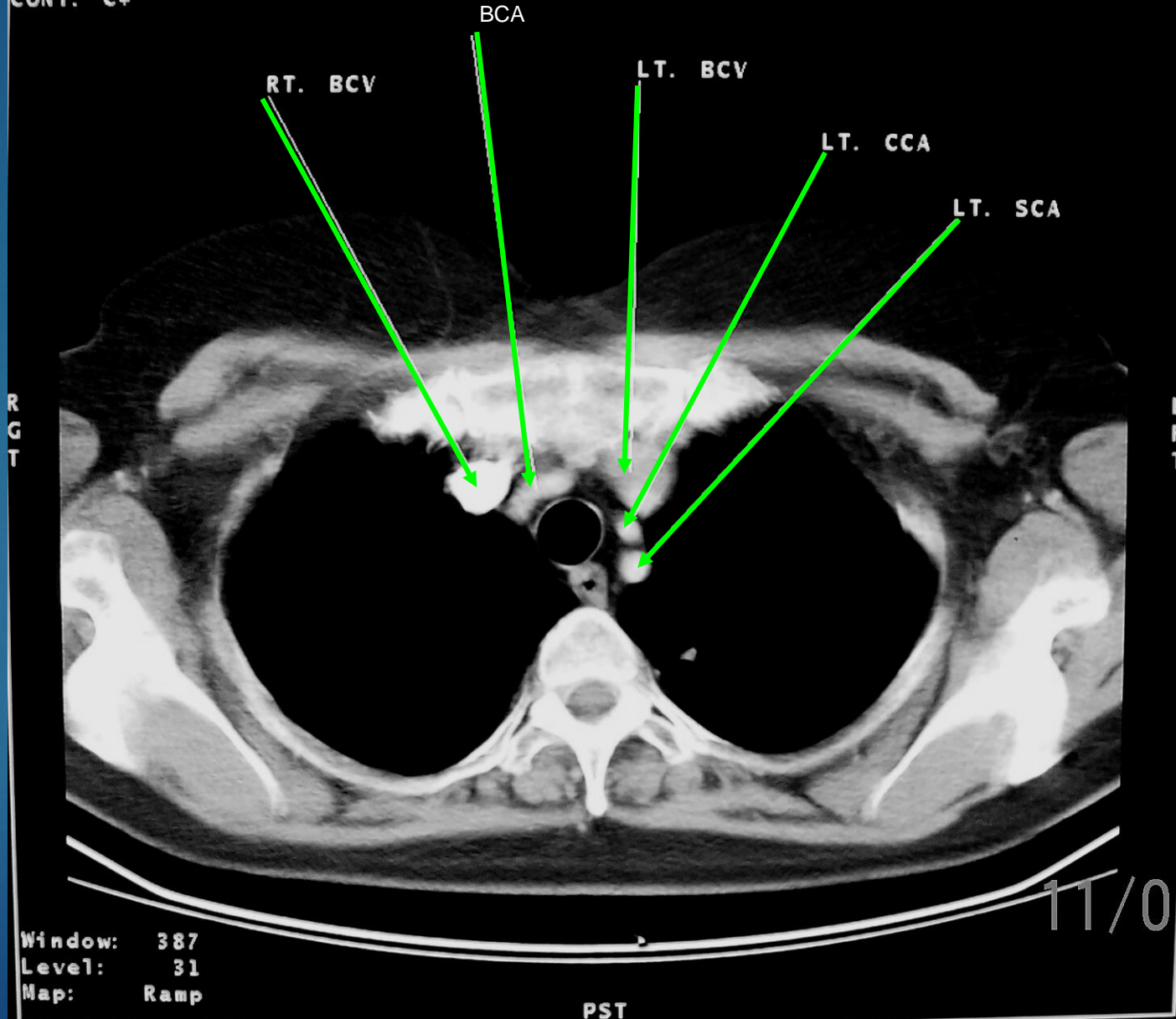


BETHESDA OAK HOSPITAL
PQ2000 3317
07-Mar-96 09:41
Patient Name
ID: 1150472
CONT: C+

ANT

2-D #6
Active

Loc: 801 mm
X: 1.1 mm
Y: -3.0 mm
Z: -801.7 mm
Zoom: 1.60 X

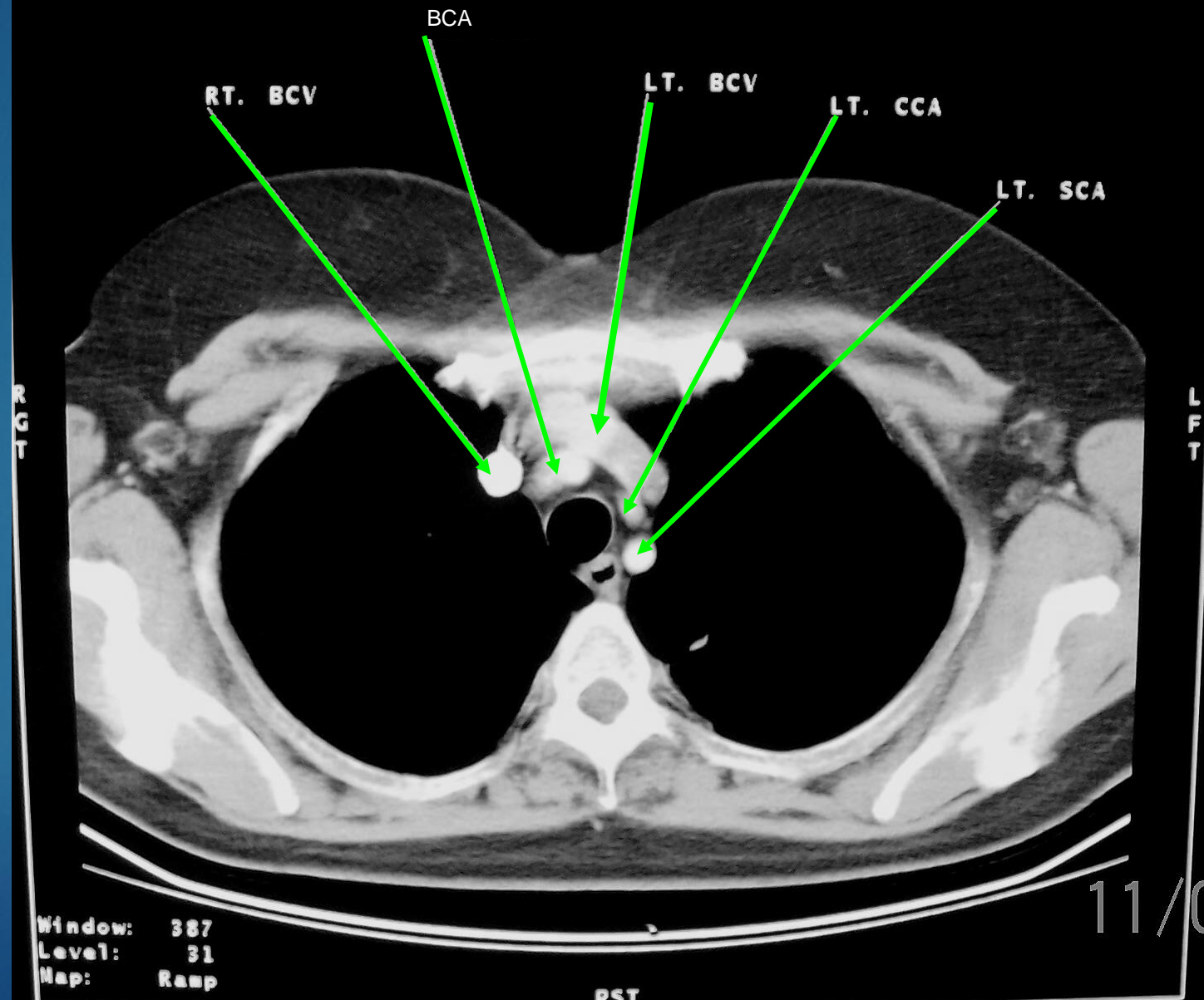


BETHESDA OAK HOSPITAL
PQ2000 3317
D7-Mar-96 09:41
Patient Name
ID: 1150472
CONT: C+

ANT

2-D #7
Active

Loc: 811 mm
X : 1.1 mm
Y : -3.0 mm
Z : -811.7 mm
Zoom: 1.60 X

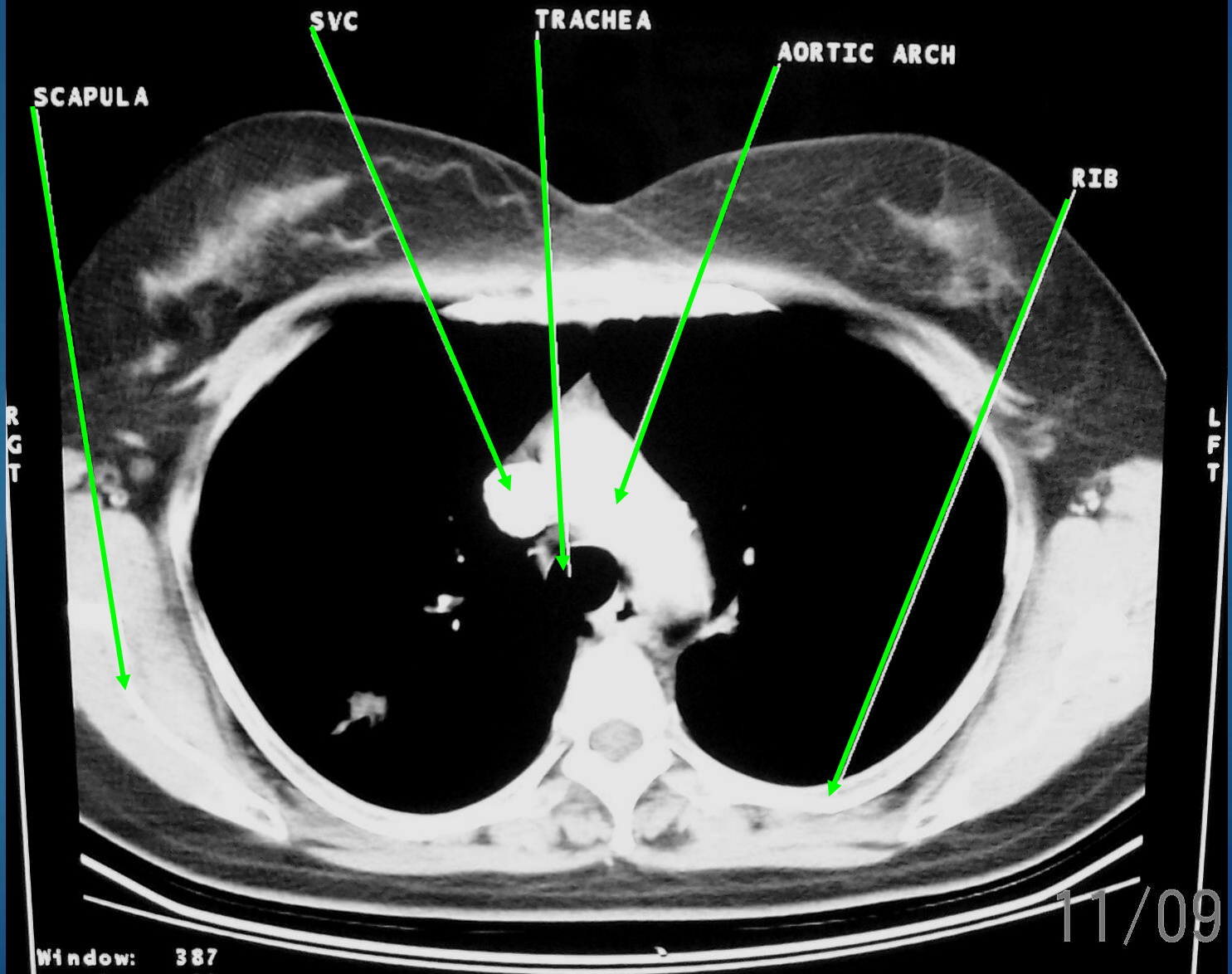


BETHESDA OAK HOSPITAL
PQ2000 3317
07-Mar-96 09:41
Patient Name
ID: 1150472
CONT: C+

ANT

2-D #10
Active

Loc: 841 mm
X : 1.1 mm
Y : -3.0 mm
Z : -841.8 mm
Zoom: 1.60 X



Window: 387
Level: 31
Map: Ramp

PST

11/09

BETHESDA OAK HOSPITAL
PQ2000 3317
07-Mar-96 09:41
Patient Name
ID: 1150472
CONT: C+

ANT

2-D #13
Active

Loc: 871 mm
X : 1.1 mm
Y : -3.0 mm
Z : -871.8 mm
Zoom: 1.60 X

SVC

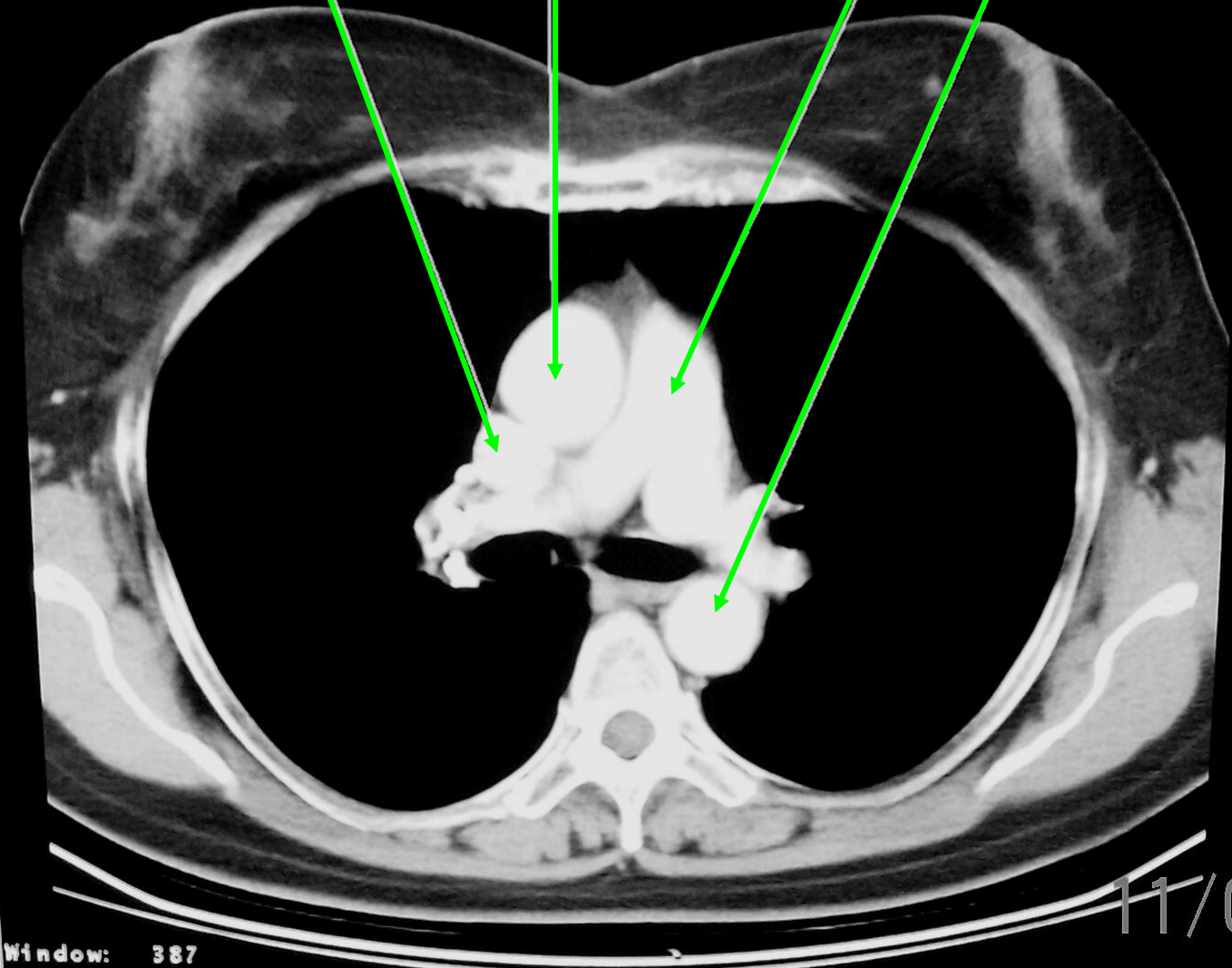
ASCENDING AORTA

PULMONARY TRUNK

DESCENDING AORTA

R
T
G

L
F
T



Window: 387
Level: 31
Map: Ramp

PST

11/09

BETHESDA OAK HOSPITAL
PQ2000 3317
07-Mar-96 09:41
Patient Name
ID: 1150472
CONT: C+

ANT

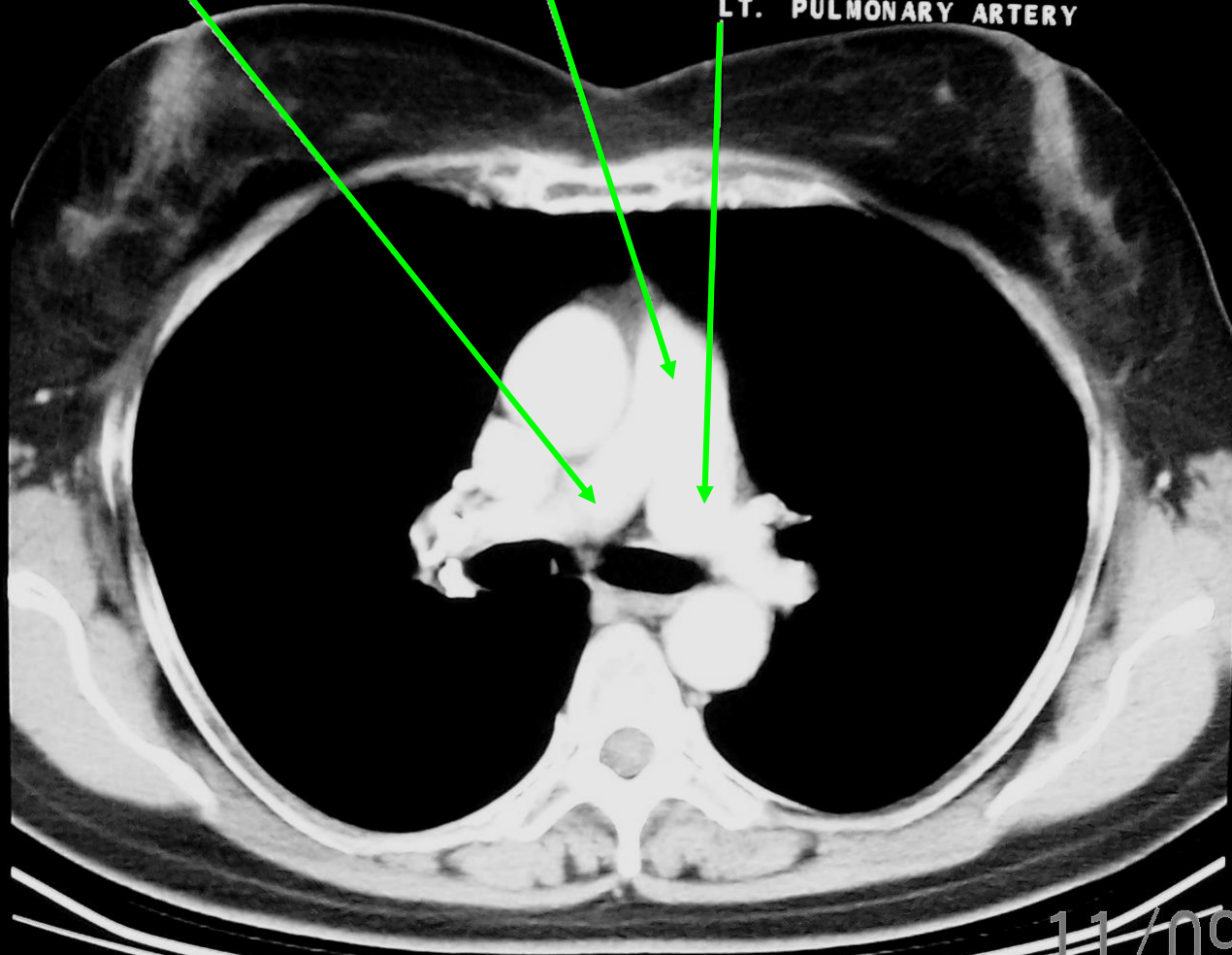
2-D #13
Active

Loc: 871 mm
X: 1.1 mm
Y: -3.0 mm
Z: -871.8 mm
Zoom: 1.60 X

MAIN PULMONARY ARTERY

RT. PULMONARY ARTERY

LT. PULMONARY ARTERY



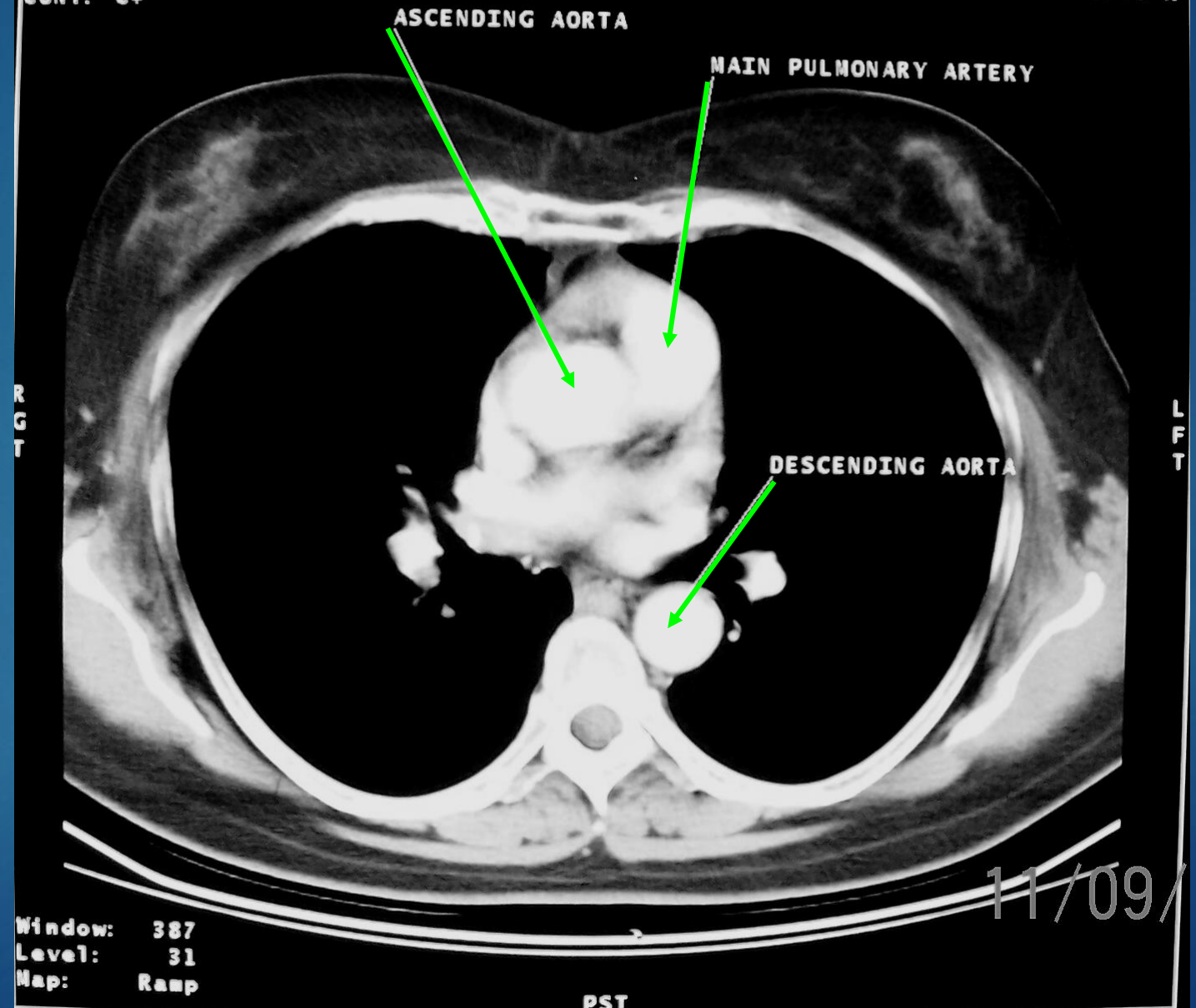
Window: 387
Level: 31
Map: Ramp

PST

BETHESDA CAR HOSPITAL
PQ2000 3317
07-Mar-96 09:41
Patient Name
ID: 1150472
CONT: C+

ANI 2-D #15
Active

Loc: 891 mm
X: 1.1 mm
Y: -3.0 mm
Z: -891.8 mm
Zoom: 1.60 X



BETHESDA OAK HOSPITAL
PQ2000 3317
07-Mar-96 09:41
Patient Name
ID: 1150472
CONT: C+

ANT

2-D #17
Active

Loc: 911 mm
X : 1.1 mm
Y : -3.0 mm
Z : -911.8 mm
Zoom: 1.60 X

RT. ATRIUM

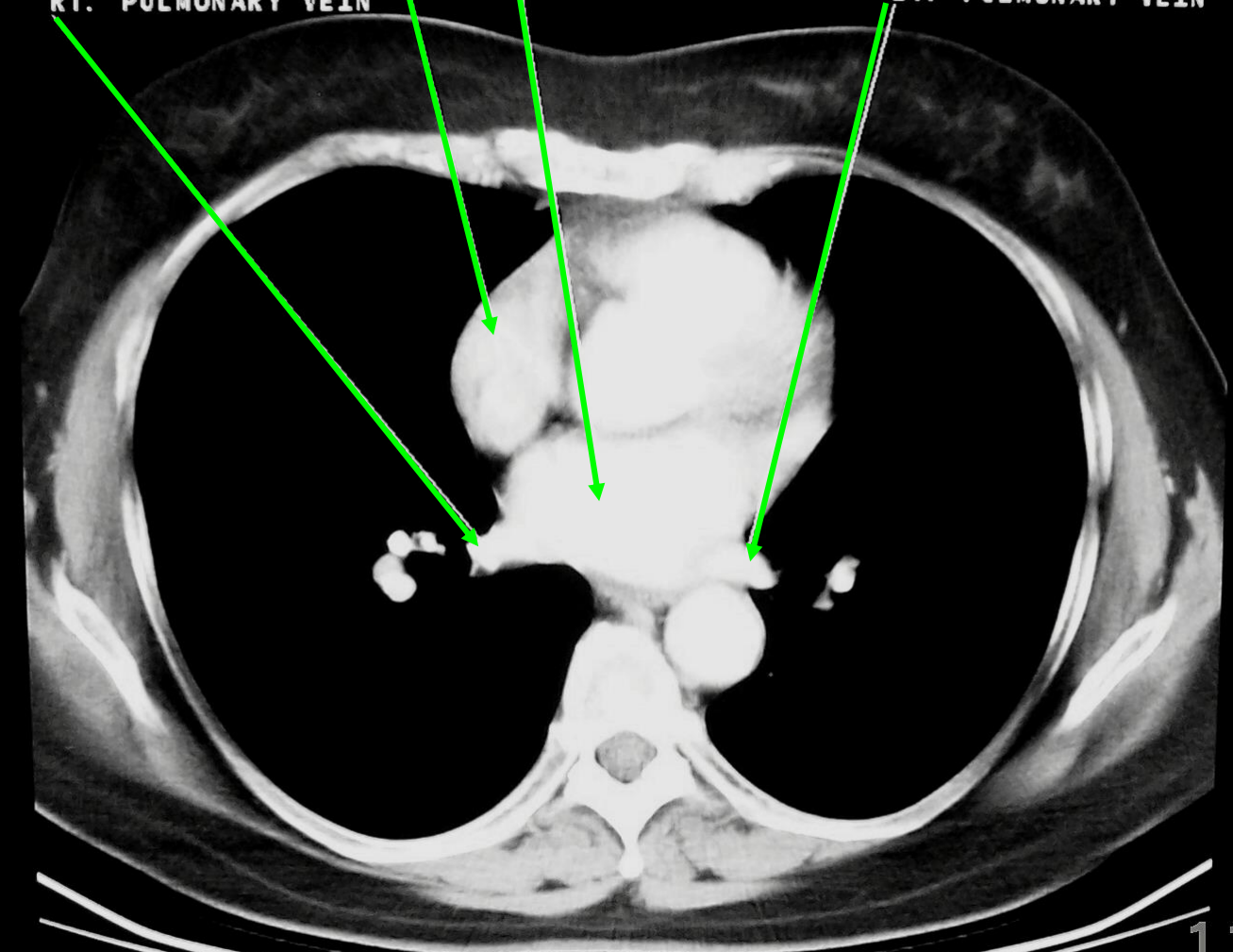
LT. ATRIUM

RT. PULMONARY VEIN

LT. PULMONARY VEIN

R
G
T

L
F
T



Window: 387
Level: 31
Map: Ramp

PST

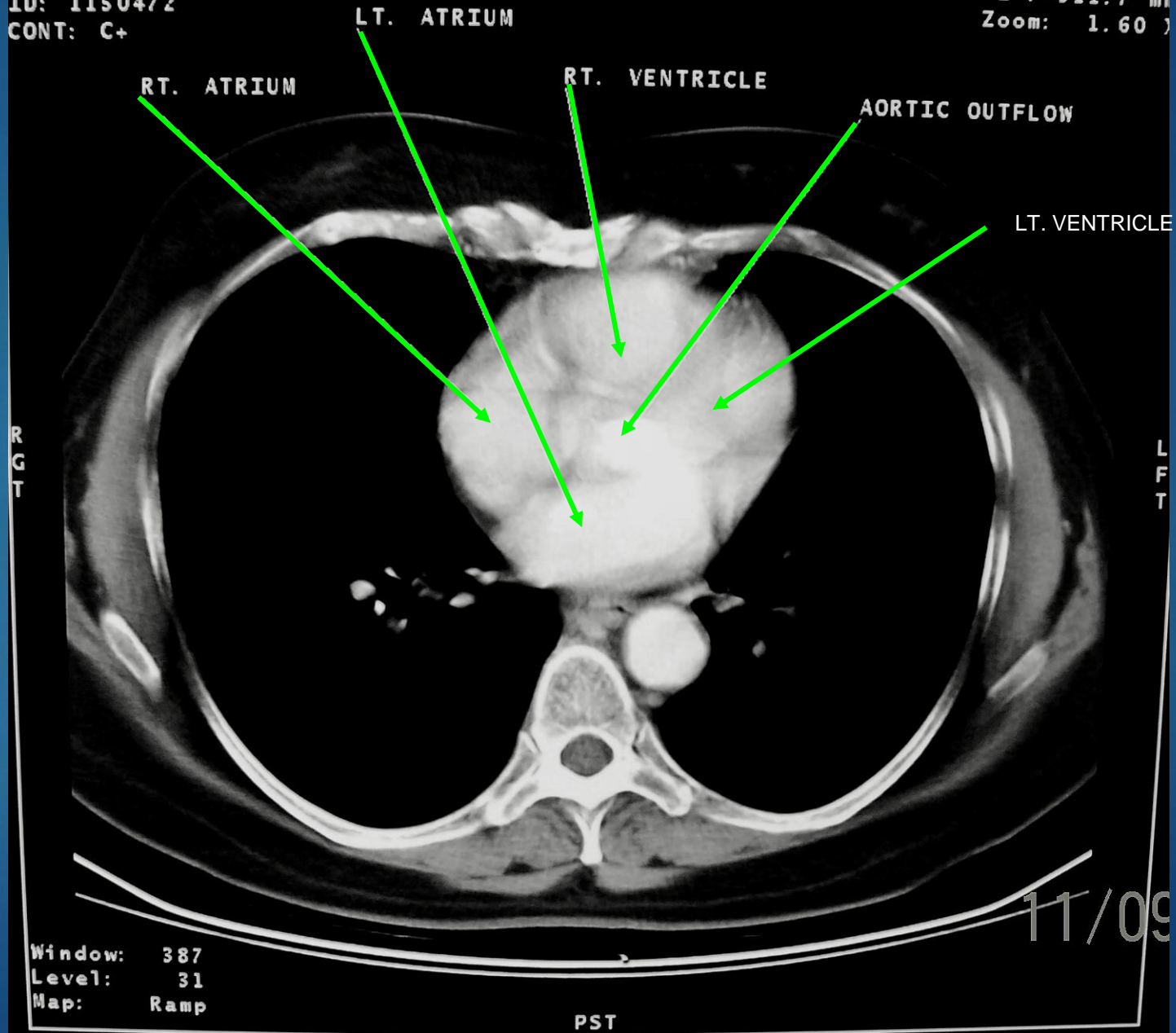
11

BETHESDA OAK HOSPITAL
PQ2000 3317
07-Mar-96 09:41
Patient Name
ID: 1150472
CONT: C+

ANT

2-D #18
Active

Loc: 921 mm
X : 1.1 mm
Y : -3.0 mm
Z : -921.7 mm
Zoom: 1.60



BETHESDA OAK HOSPITAL
PQ2000 3317
07-Mar-96 09:41
Patient Name
ID: 1150472
CONT: C+

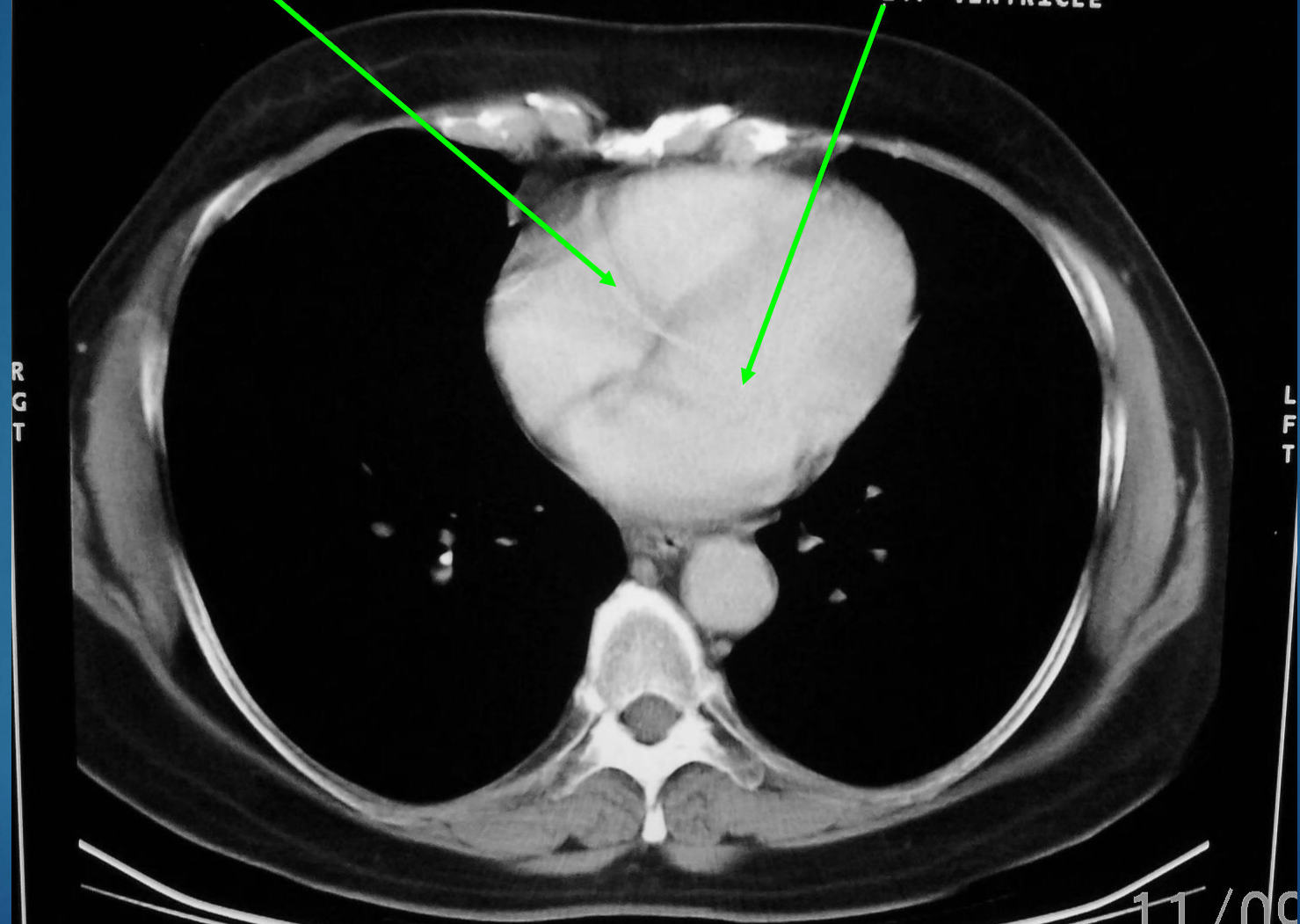
ANT

2-D #19
Active

Loc: 931 m
X : 1.1 m
Y : -3.0 m
Z : -931.7 m
Zoom: 1.60

RT. VENTRICLE

LT. VENTRICLE



Window: 387
Level: 31
Map: Ramp

PST

11/09

BETHESDA OAK HOSPITAL
PQ2000 3317
07-Mar-96 09:41
Patient Name
ID: 1150472
CONT: C+

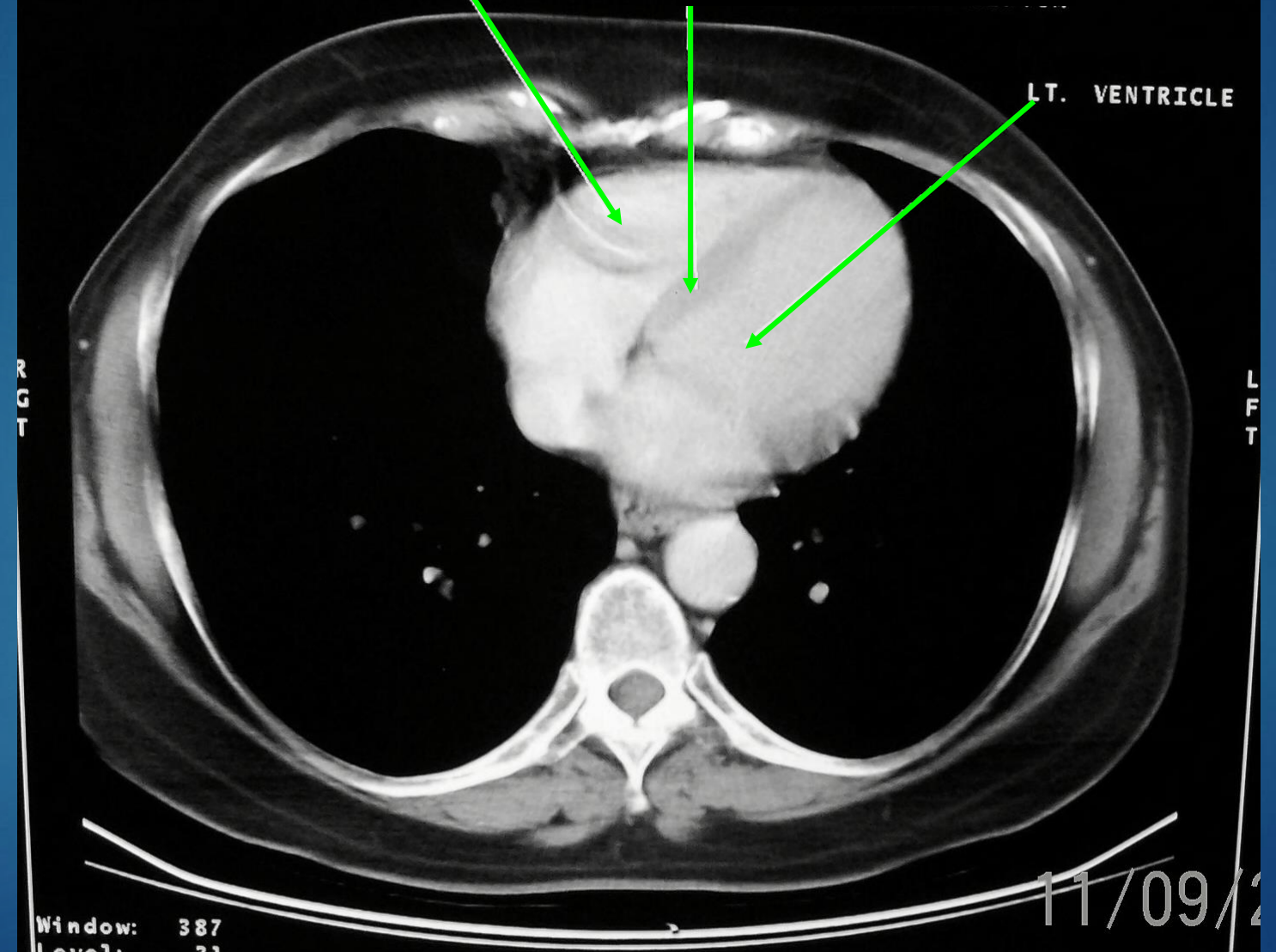
ANT 2-D #20
Active

Loc: 941 mm
X: 1.1 mm
Y: -3.0 mm
Z: -941.7 mm
Zoom: 1.60 X

RT. VENTRICLE

INTERVENTRICULAR SEPTUM

LT. VENTRICLE



Window: 387
Level: 31
Map: Ramp

PST

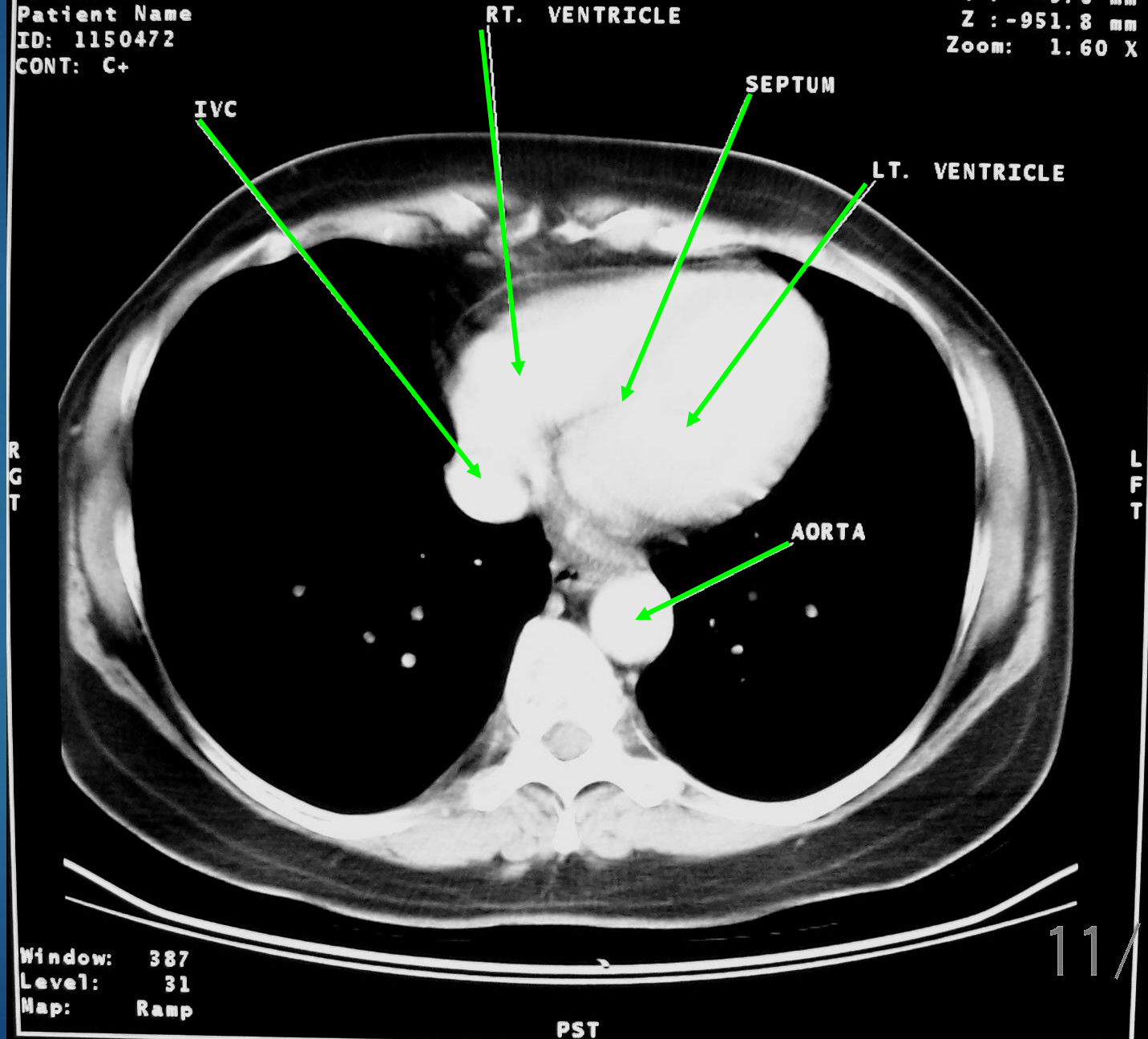
11/09/96

BETHESDA OAK HOSPITAL
PQ2000 3317
07-Mar-96 09:41
Patient Name
ID: 1150472
CONT: C+

ANT

2-D #21
Active

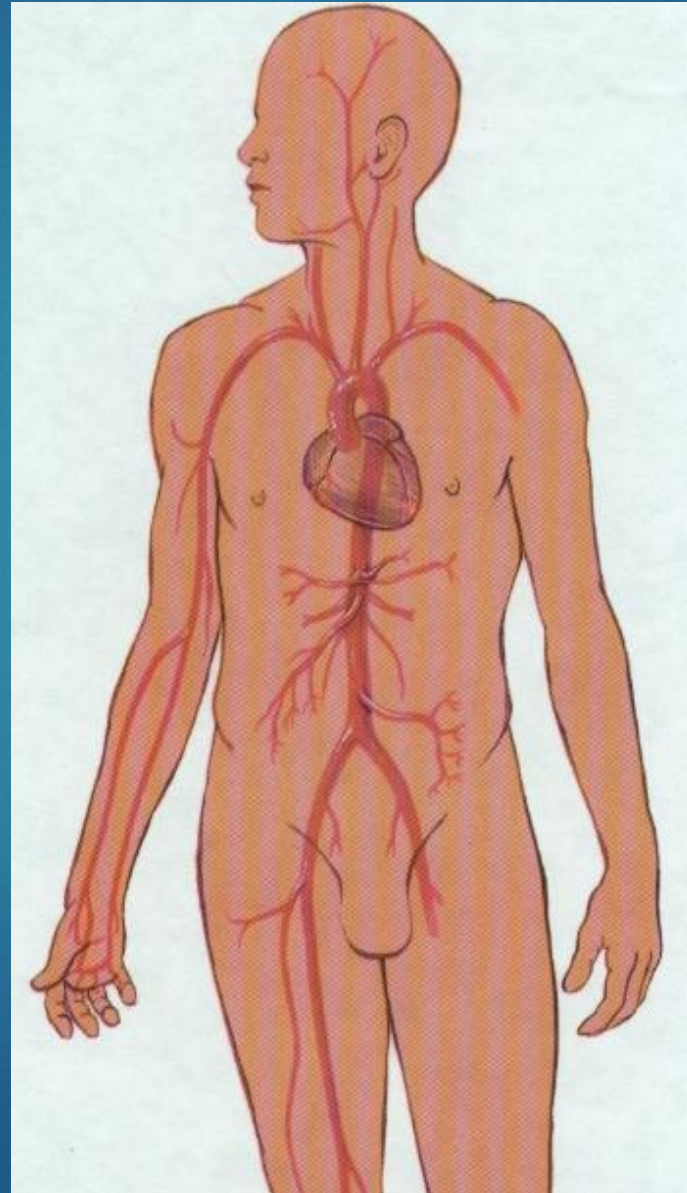
Loc: 951 mm
X : 1.1 mm
Y : -3.0 mm
Z : -951.8 mm
Zoom: 1.60 X



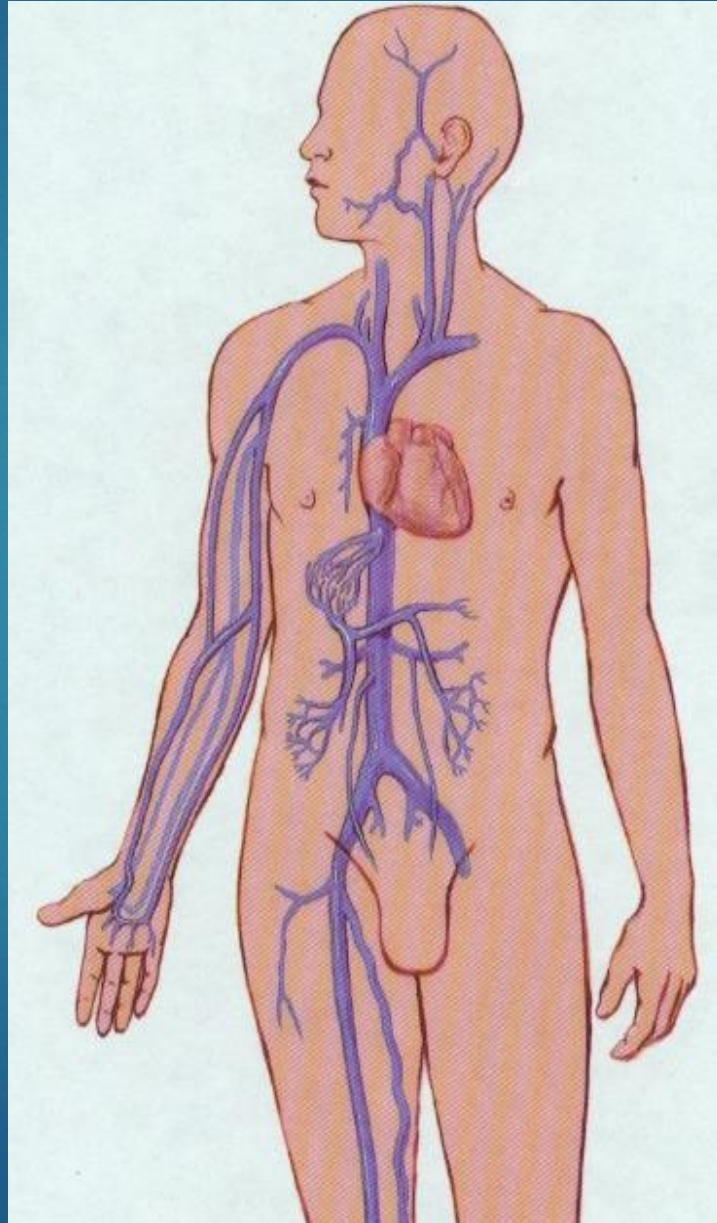


Anatomy of the Abdomen and Pelvis

Arterial Anatomy

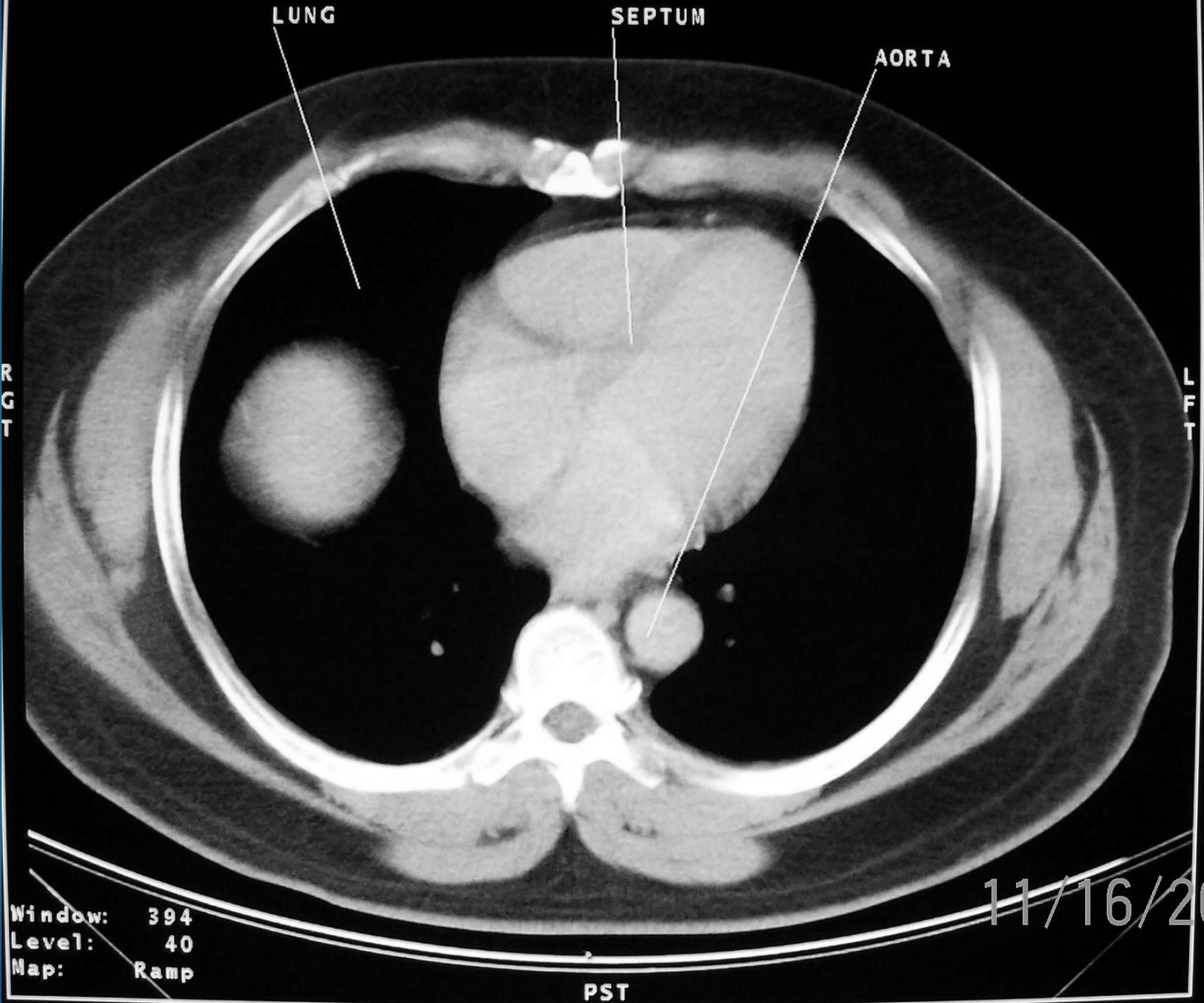


Venous Anatomy



Patient Name
ID: 0837594
CONT: C+

Z: -1045.1 mm
Zoom: 1.75 X



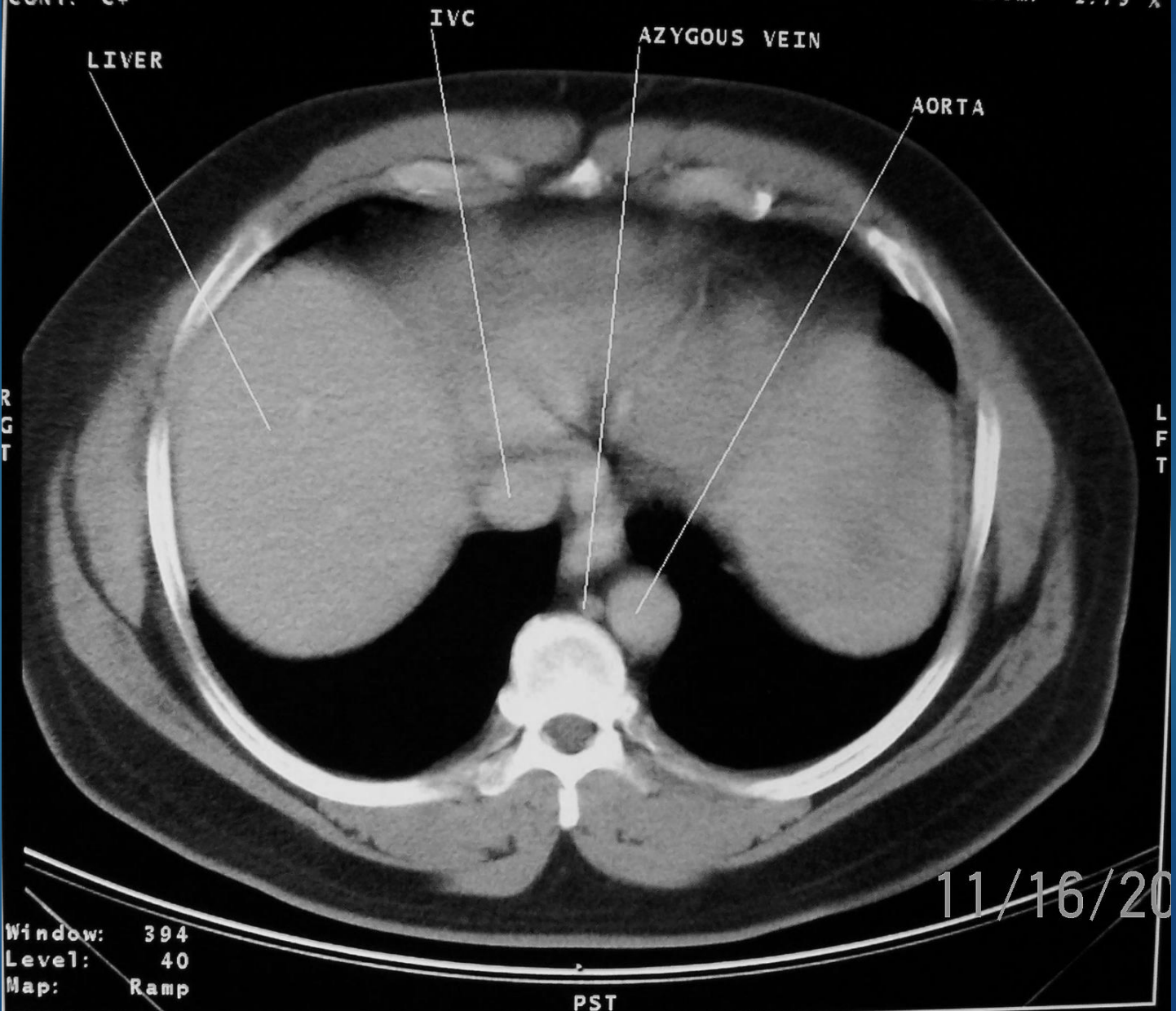
Window: 394
Level: 40
Map: Ramp

11/16/20

PST

20-Dec-95 09:50
Patient Name
ID: 0837594
CONT: C+

X: -4.9 mm
Y: -34.0 mm
Z: -1075.1 mm
Zoom: 1.75 X



Window: 394
Level: 40
Map: Ramp

11/16/20

PST

ID: 0837594
CONT: C+

Z : -1095.1 mm
Zoom: 1.75 X

RT. LOBE OF LIVER

ESOPHAGUS

STOMACH

SPLEEN

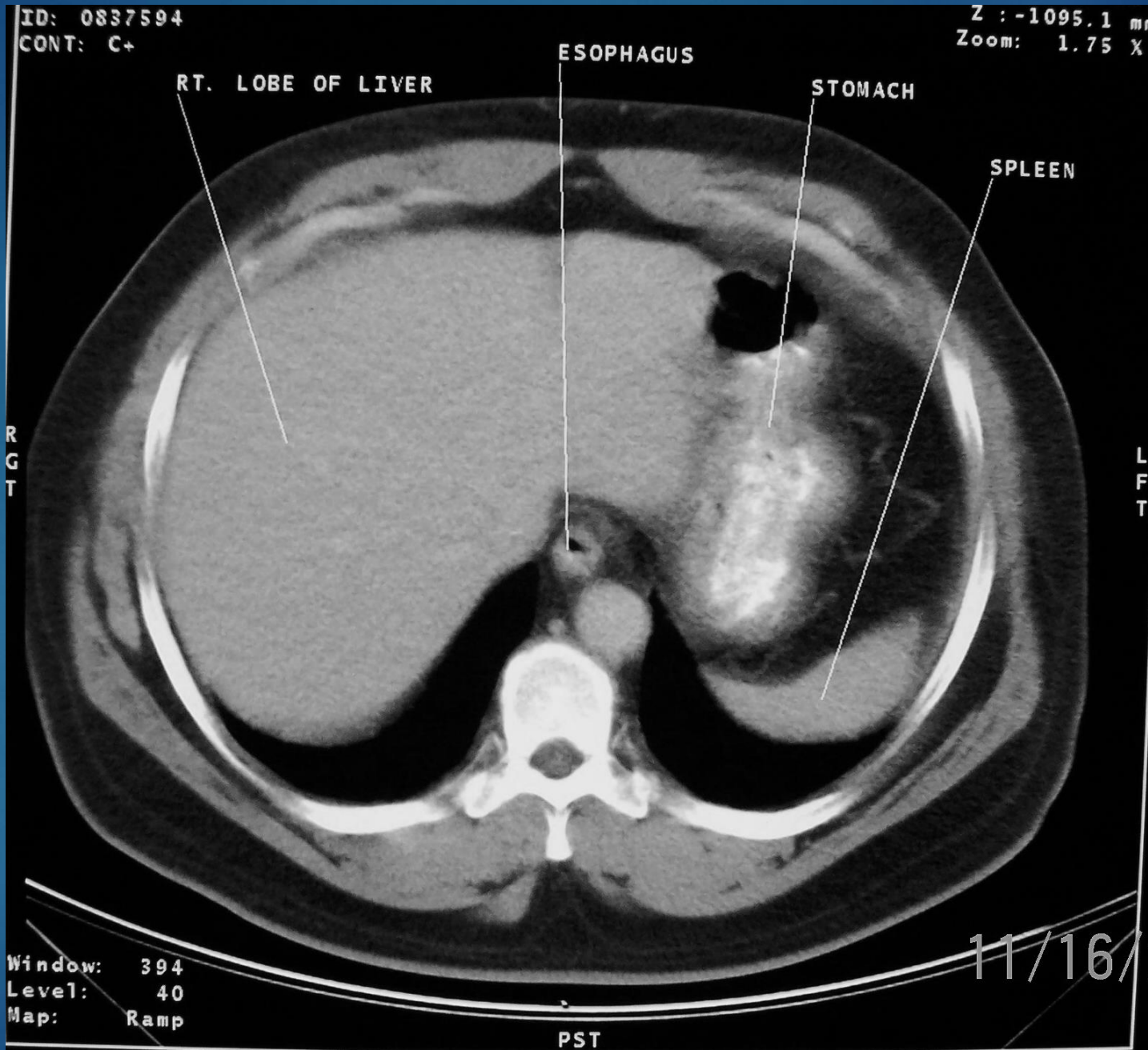
R
G
T

L
F
T

Window: 394
Level: 40
Map: Ramp

11/16/

PST



20 00:00 09:30
Patient Name
ID: 0837594
CONT: C+

X : -4.9 mm
Y : -34.0 mm
Z : -1105.1 m
Zoom: 1.75 X

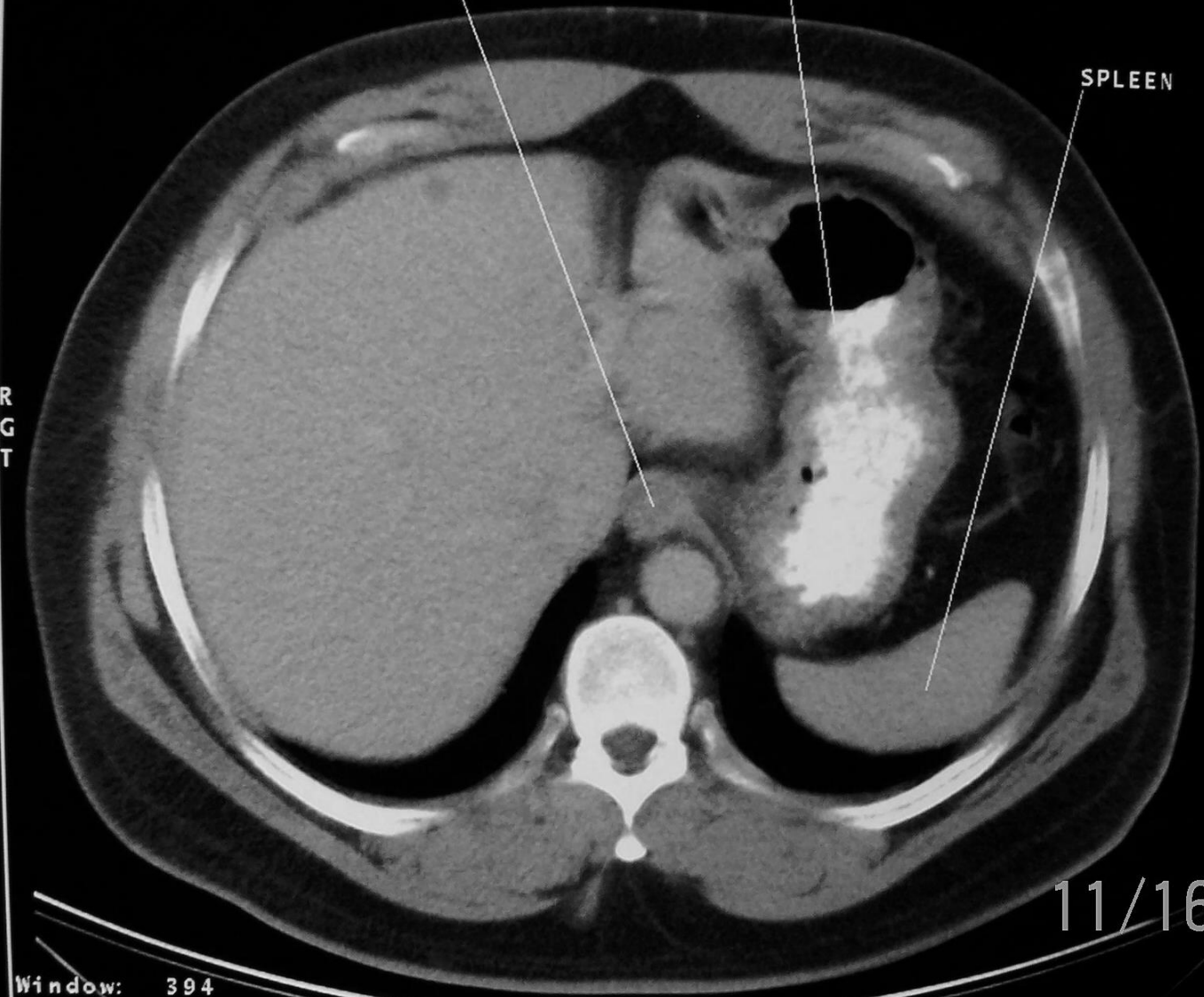
ESOPHAGUS

STOMACH

SPLEEN

R
G
T

L
F
T



Window: 394
Level: 40
Map: Ramp

PST

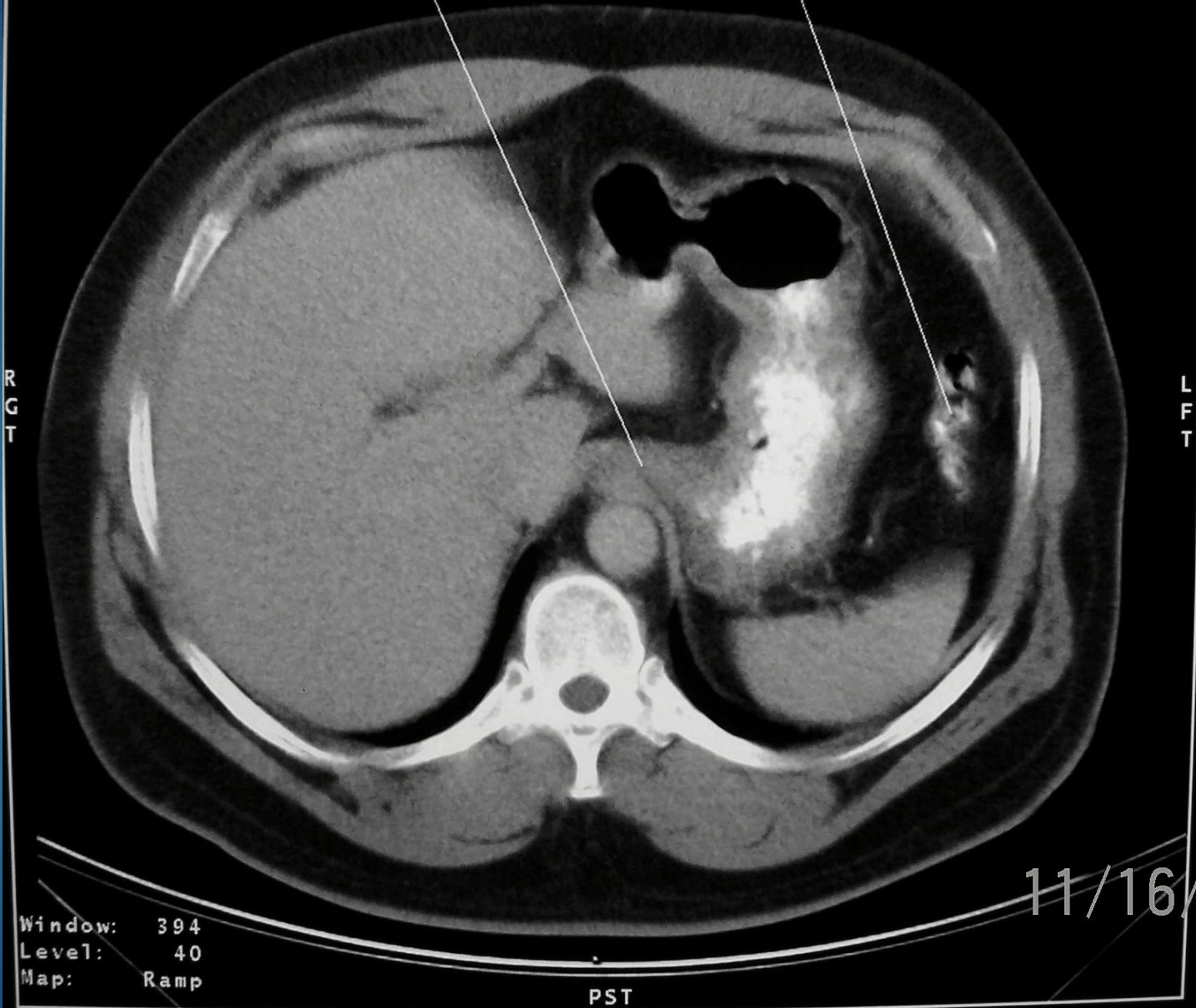
11/16/2

Patient Name
ID: 0837594
CONT: C+

-54.0 mm
Z: -1115.1 mm
Zoom: 1.75 X

CARDIAC ORIFACE

DESCENDING COLON



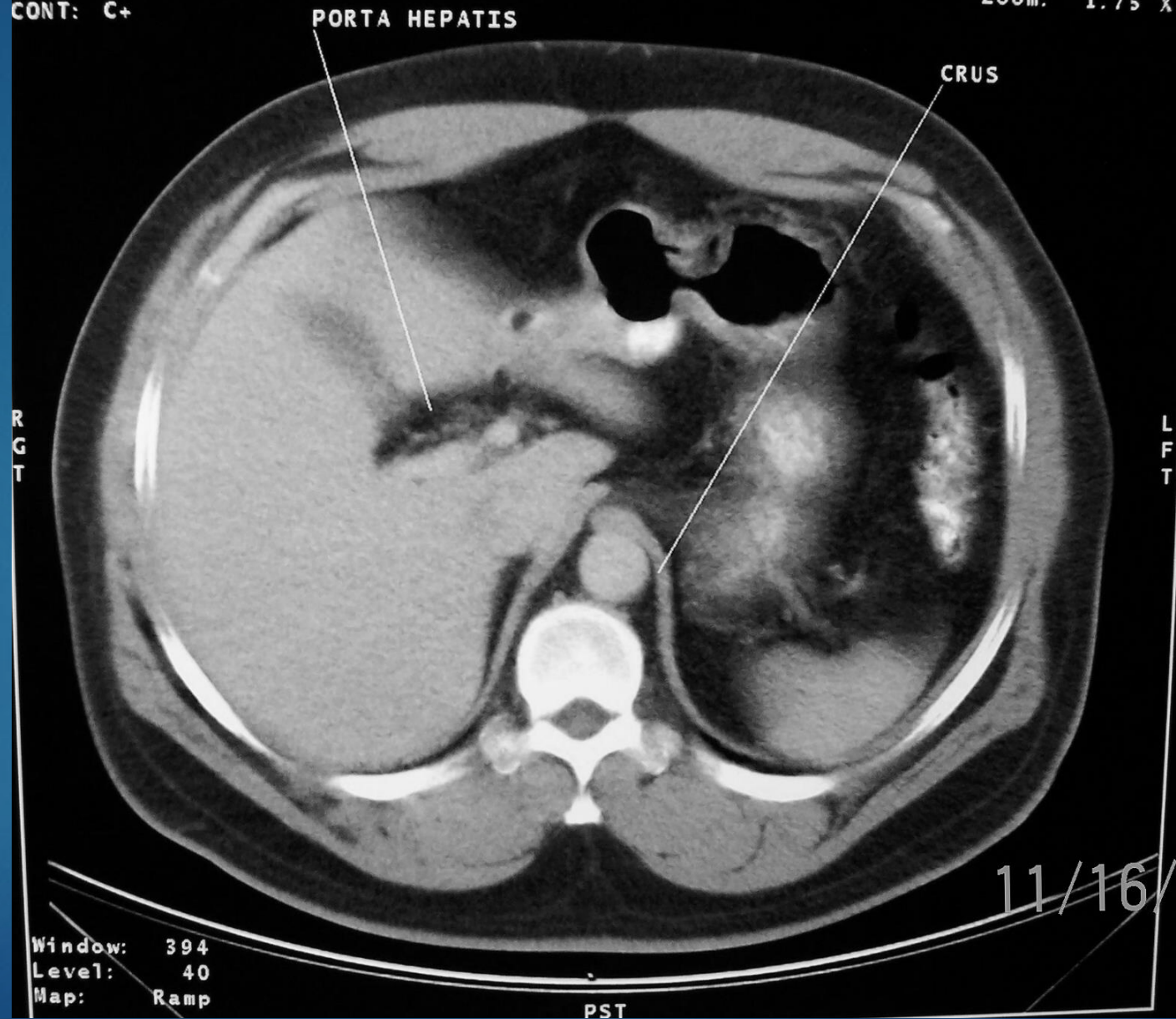
Window: 394
Level: 40
Map: Ramp

11/16

PST

20-Dec-95 09:38
Patient Name
ID: 0837594
CONT: C+

X : -4.9 mm
Y : -34.0 mm
Z : -1125.1 mm
Zoom: 1.75 X



BETHESDA OAK HOSPITAL
PQ2000 2619
20-Dec-95 09:38
Patient Name
ID: 0837594
CONT: C+

ANT

2-D #13
Active

Loc: 1135 mm
X: -5.5 mm
Y: -18.0 mm
Z: -1135.1 m
Zoom: 1.75 X

GALLBLADDER

IVC

AORTA

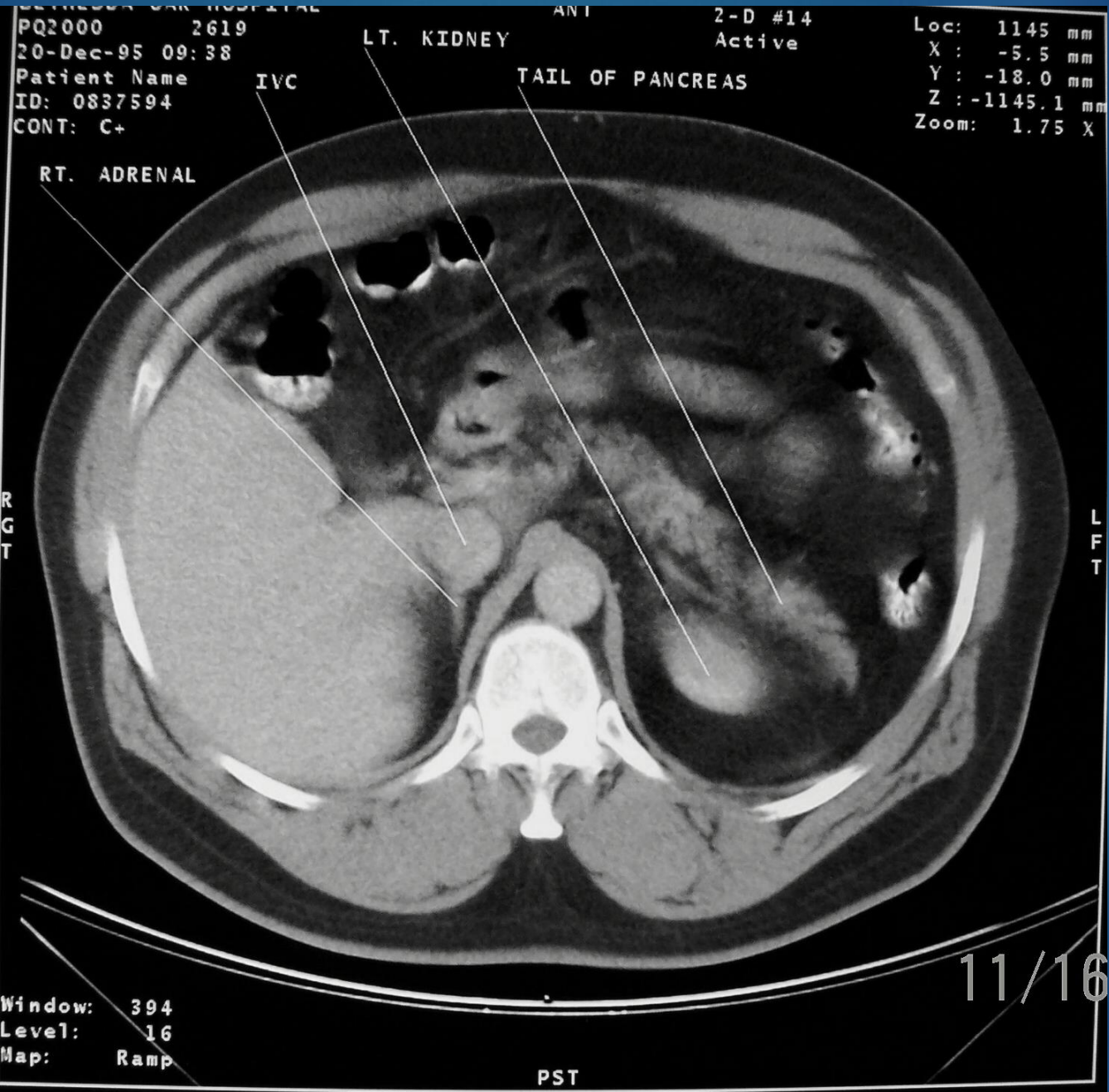
R
G
T

L
F
T

Window: 400
Level: 40
Map: Ramp

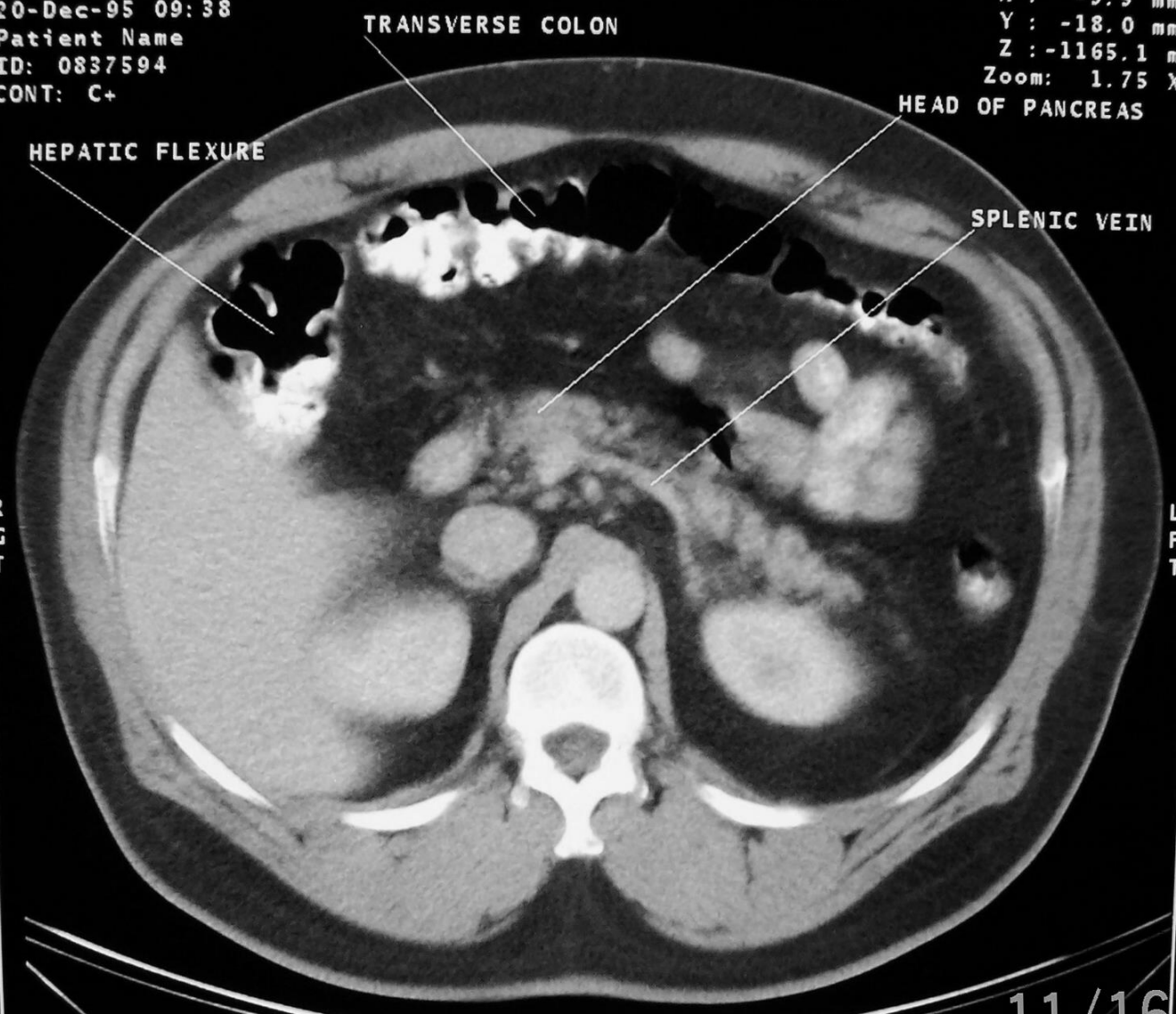
PST

11/16



PQ2000 2619
20-Dec-95 09:38
Patient Name
ID: 0837594
CONT: C+

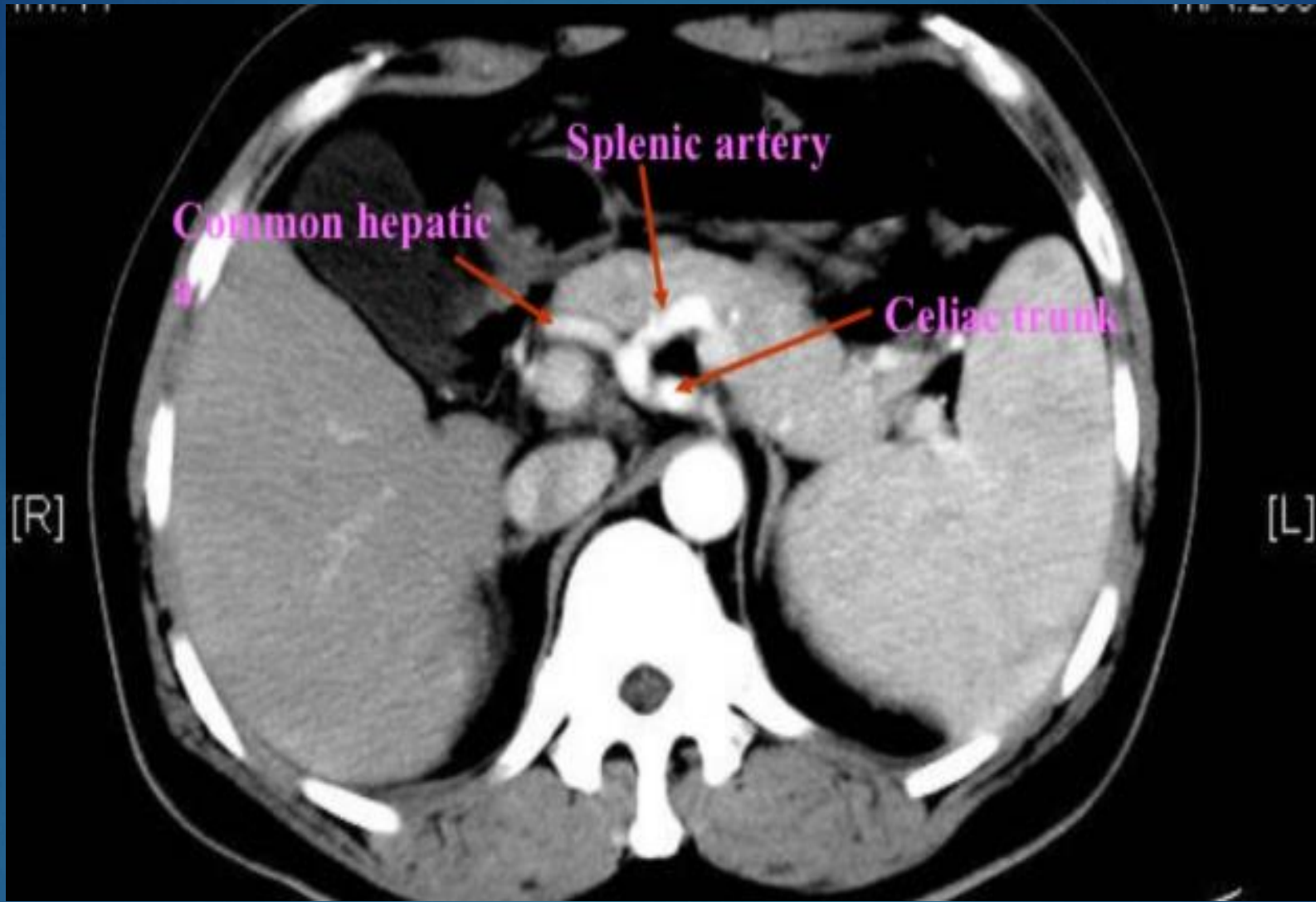
Active
Loc: 1165 mm
X : -5.5 mm
Y : -18.0 mm
Z : -1165.1 mm
Zoom: 1.75 X



Window: 394
Level: 16
Map: Ramp

11/16

PST



BETHESDA OAK HOSPITAL
PQ2000 2619
20-Dec-95 09:38
Patient Name
ID: 0837594
CONT: C+

ANT

2-D #20
Active

Loc: 1205 mm
X: -5.9 mm
Y: -46.1 mm
Z: -1205.1 mm
Zoom: 1.75 X

PSOAS MUSCLE

SMA

LINEA ALBA

RECTUS ABDOMINUS

JEJUNUM

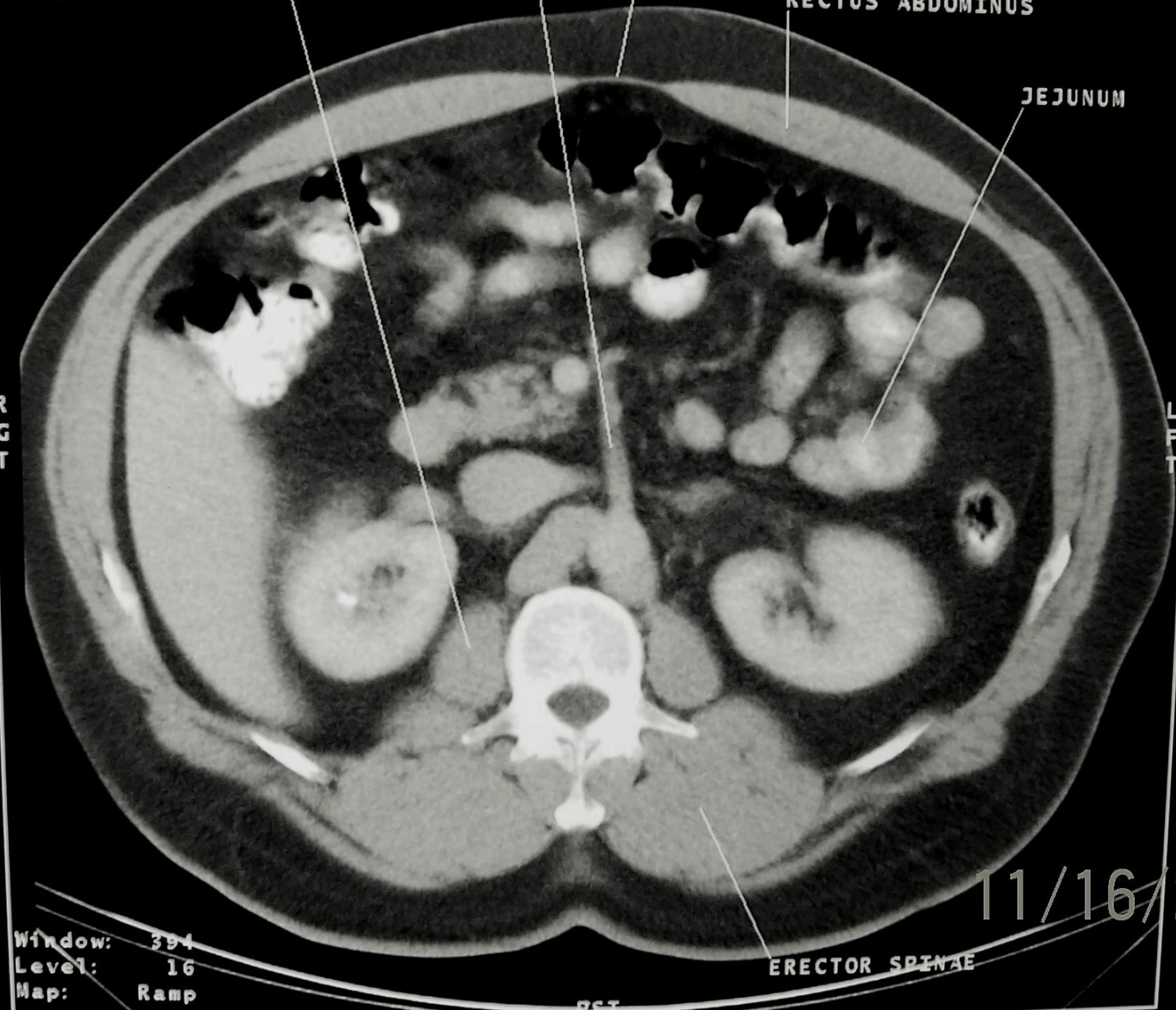
R
G
T

L
F
T

Window: 394
Level: 16
Map: Ramp

11/16/95

ERECTOR SPINAE



Patient Name
ID: 0837594
CONT: C+

Y : -46.1 mm
Z : -1215.1 m
Zoom: 1.75 X

RT. RENAL ARTERY

LT. RENAL VEIN

LT. RENAL ARTERY

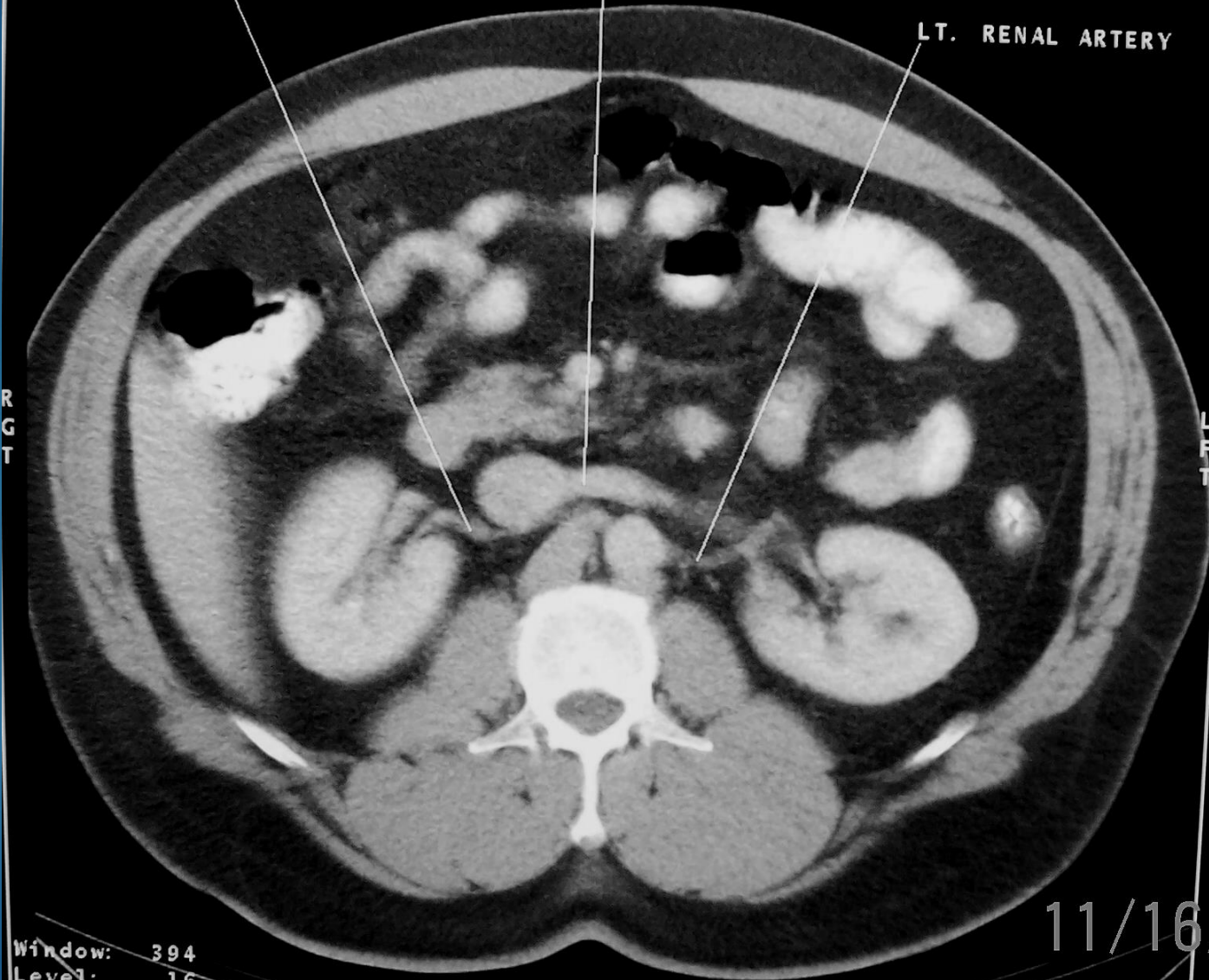
R
G
T

L
F
T

Window: 394
Level: 16
Map: Ramp

11/16

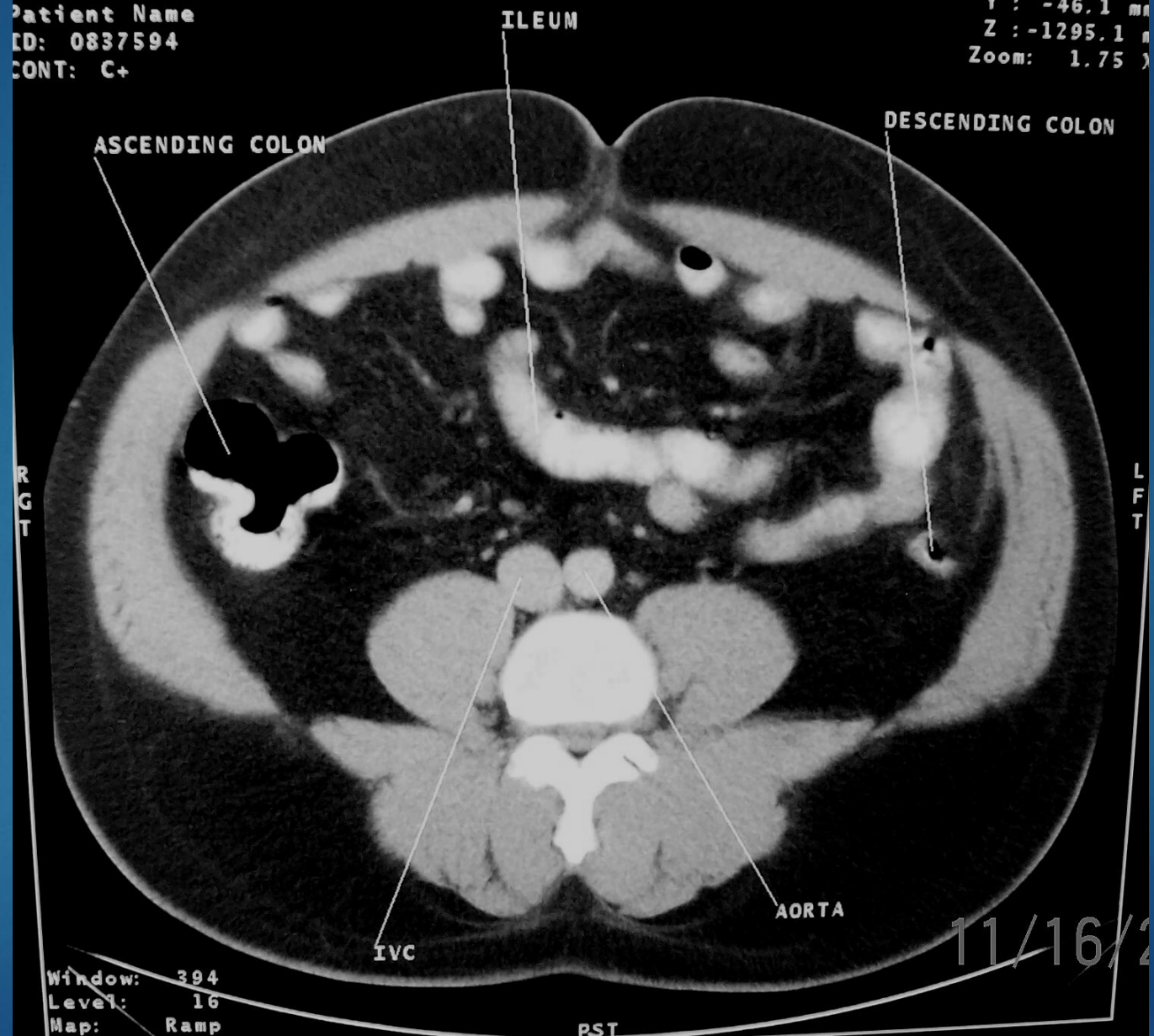
PST



SETHESOR CAR HOSPITAL
PQ2000 2619
10-Dec-95 09:38
Patient Name
ID: 0837594
CONT: C+

ANT
Z-D #29
Active

Loc: 1295 m
X: -5.9 m
Y: -46.1 m
Z: -1295.1 m
Zoom: 1.75 X



BETHESDA OAK HOSPITAL
PQ2000 2619
20-Dec-95 09:38
Patient Name
ID: 0837594
CONT: C+

ANT

2-D #31

Active

Loc: 1315 mm
X: -5.9 mm
Y: -46.1 mm
Z: -1315.1 mm
Zoom: 1.75 X

RT. CIA

LT. CIA

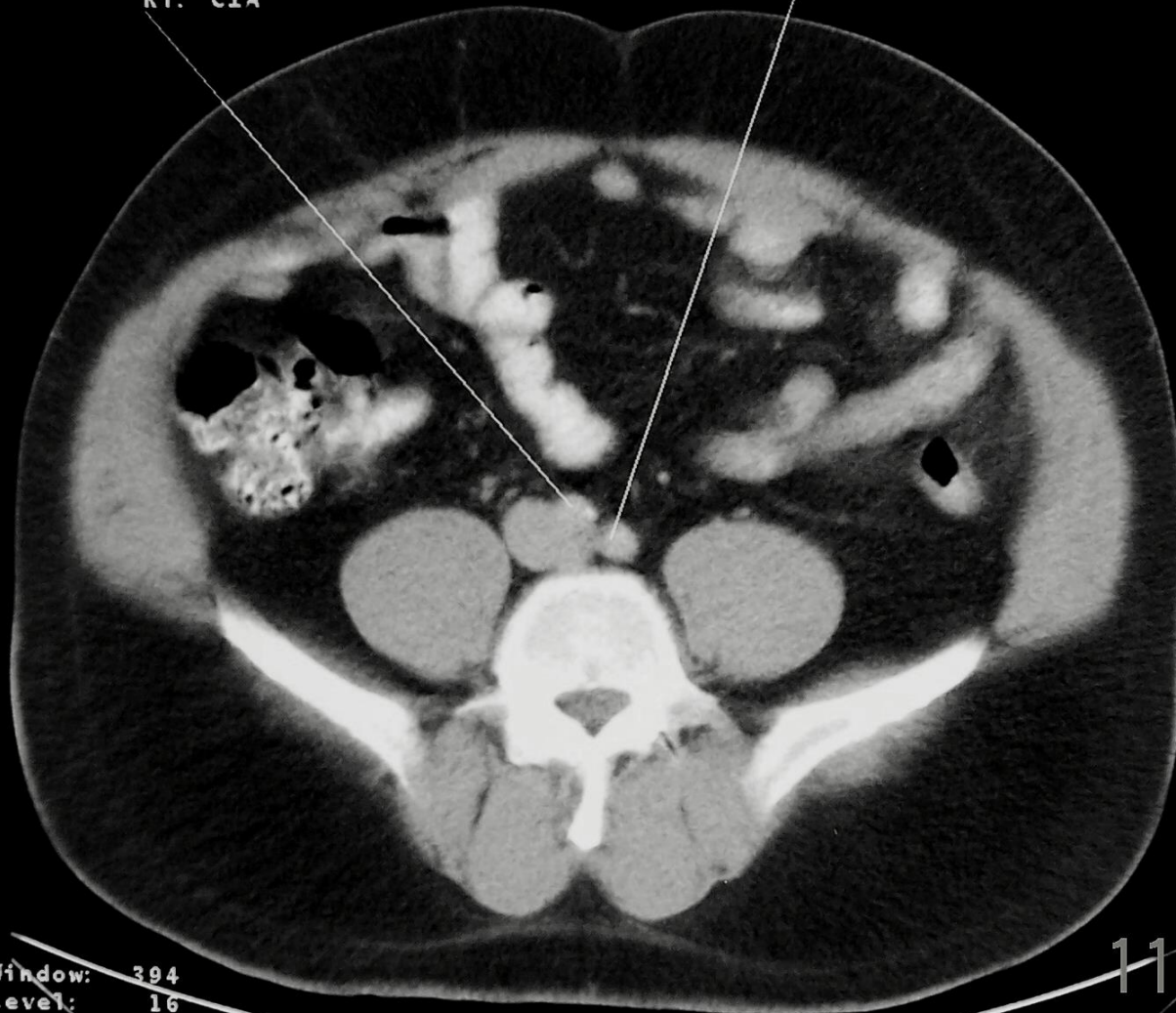
R
G
T

L
F
T

Window: 394
Level: 16
Map: Ramp

PST

11

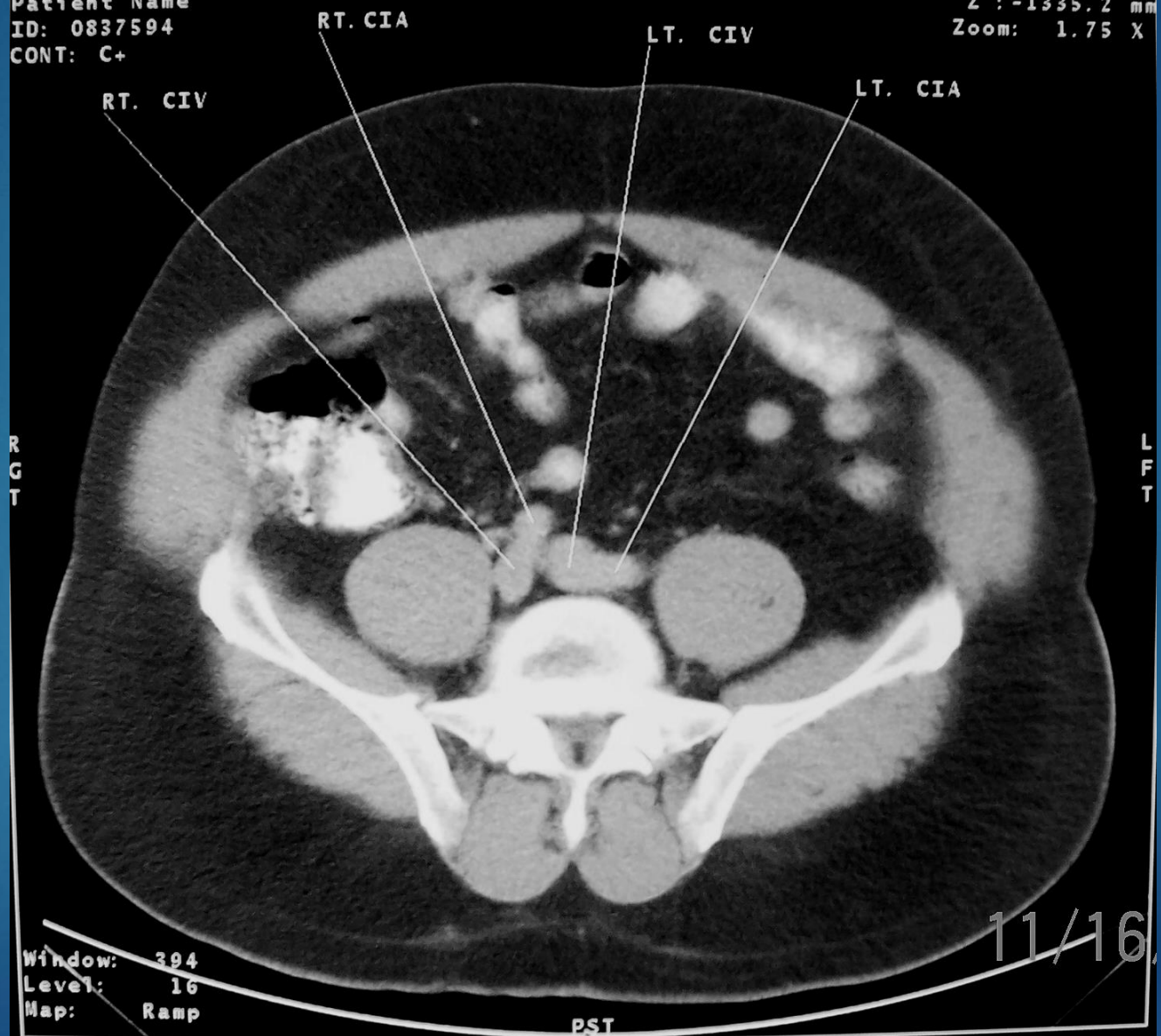


BETHESDA OAK HOSPITAL
PQ2000 2619
20-Dec-95 09:38
Patient Name
ID: 0837594
CONT: C+

ANT

2-D #33
Active

Loc: 1335 mm
X: -5.9 mm
Y: -46.1 mm
Z: -1335.2 mm
Zoom: 1.75 X

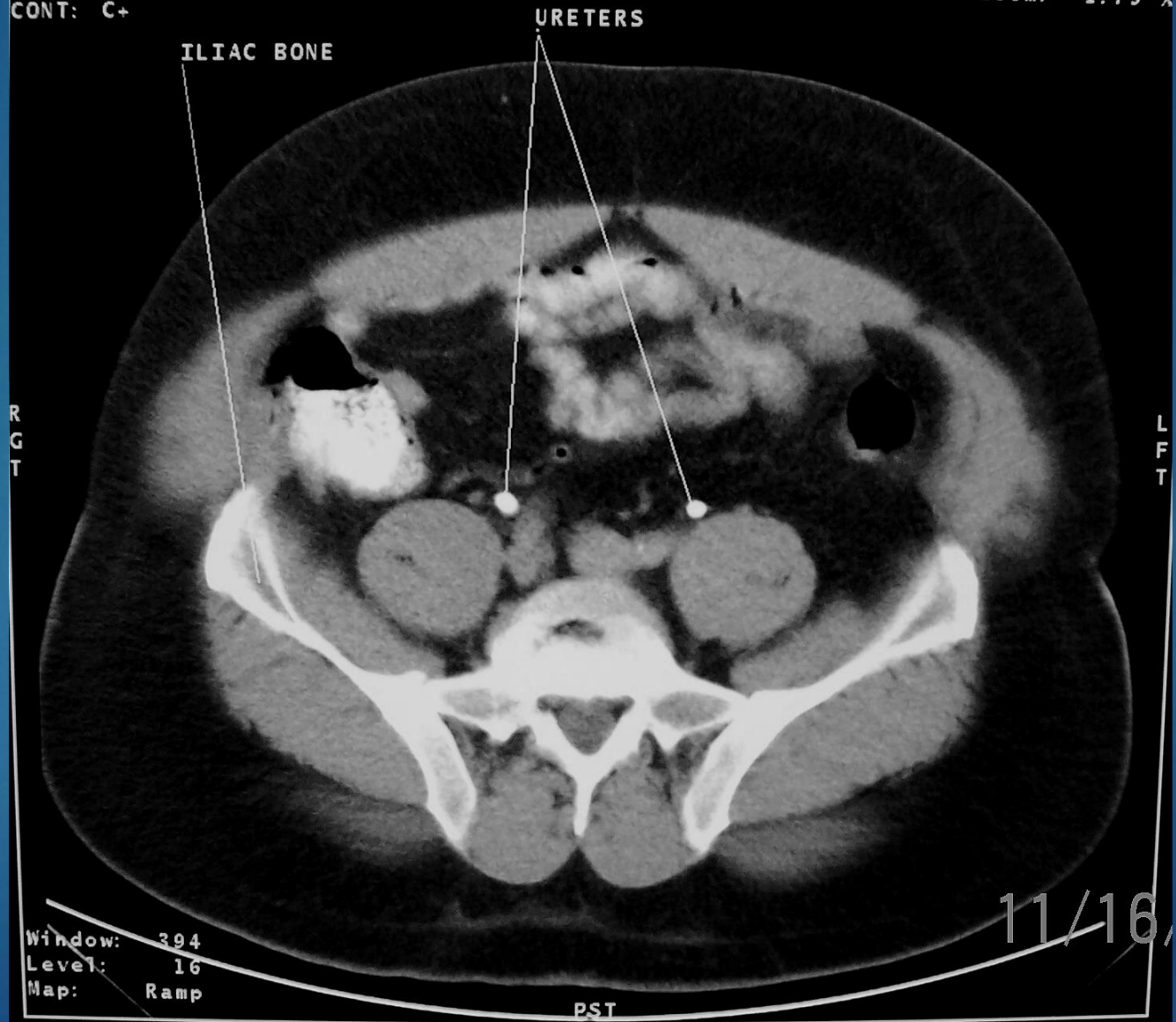


BETHESDA OAK HOSPITAL
PQ2000 2619
20-Dec-95 09:38
Patient Name
ID: 0837594
CONT: C+

ANT

2-D #34
Active

Loc: 1345 mm
X : -5.9 mm
Y : -46.1 mm
Z : -1345.1 mm
Zoom: 1.75 X



PQ2000 2619
20-Dec-95 09:38
Patient Name
ID: 0837594
CONT: C+

Z-D #36
Active

Loc: 1365 mm
X: -5.9 mm
Y: -46.1 mm
Z: -1365.1 mm
Zoom: 1.75 X

ILEOCECAL JUNCTION

SACRUM

R
G
T

L
F
T

Window: 394
Level: 16
Map: Ramp

11/16

PST

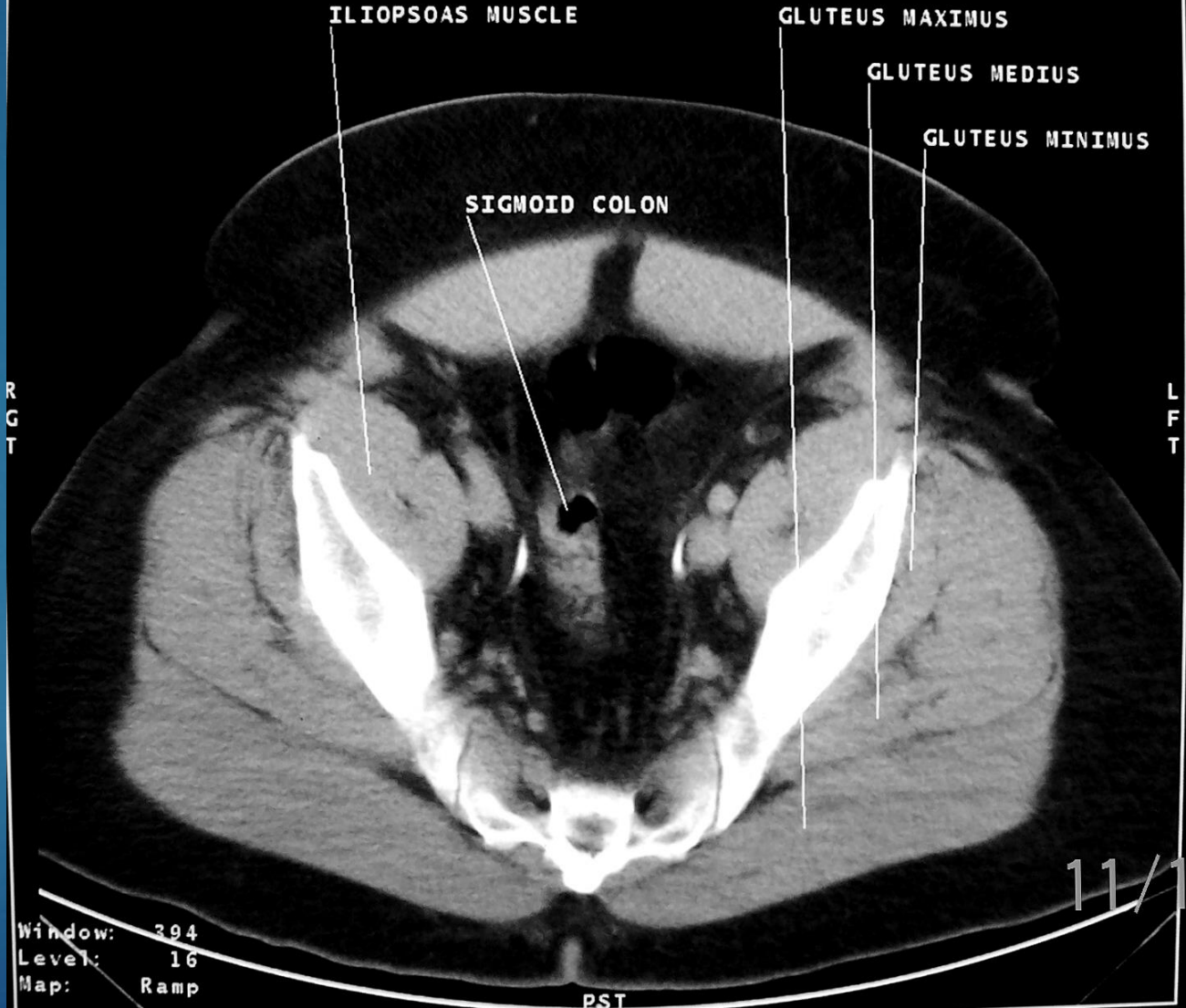

BETHESDA OAK HOSPITAL
PQ2000 2619
20-Dec-95 09:38
Patient Name
ID: 0837594
CONT: C+

ANT

2-D #40
Active

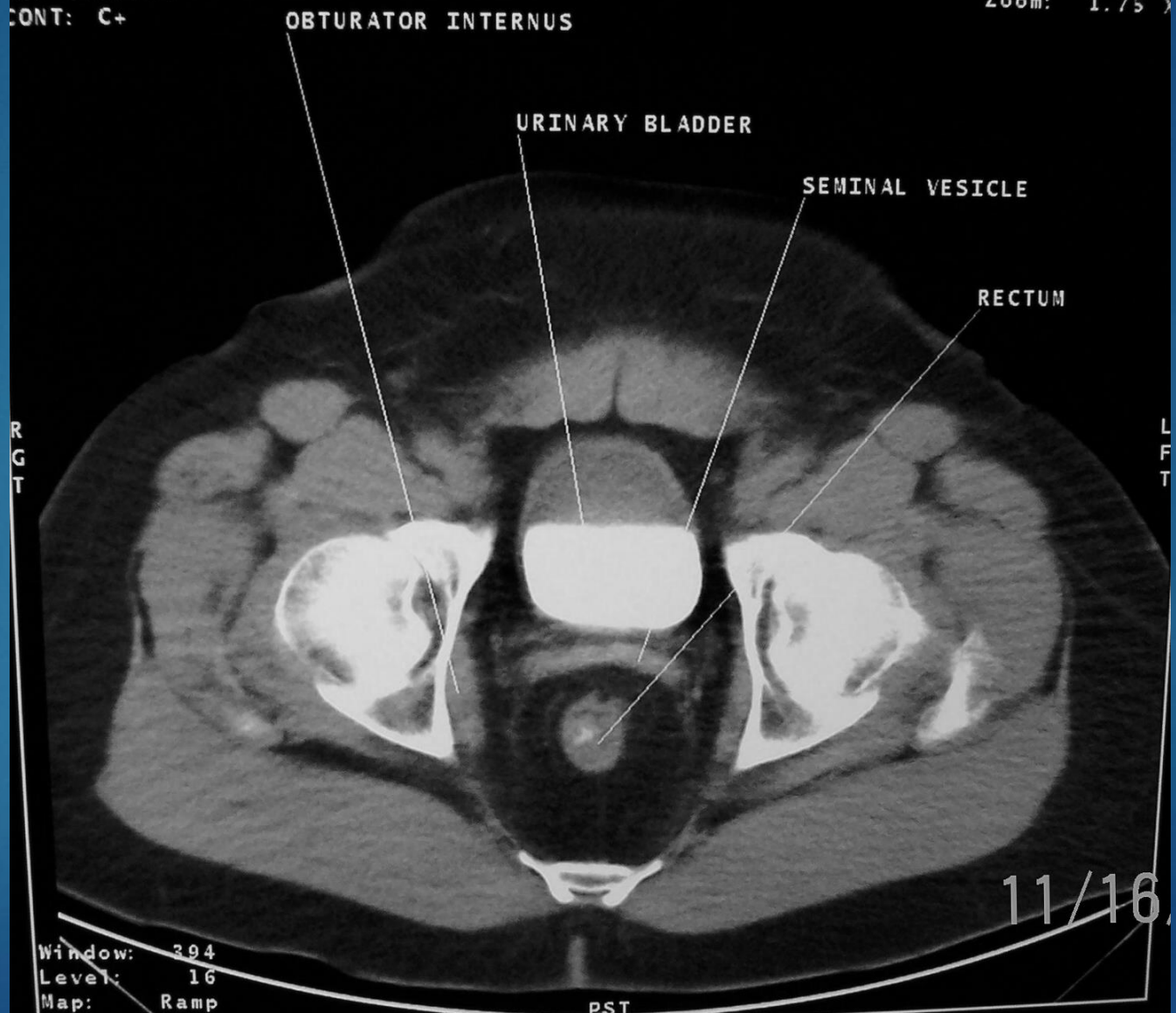Loc: 1405 mm
X : -5.9 mm
Y : -46.1 mm
Z : -1405.1 mm
Zoom: 1.75 X



Male Pelvic Anatomy

PQ2000 2619
20-Dec-95 09:38
Patient Name
ID: 0837594
CONT: C+

z-D #44
Active
Loc: 1445 mm
X : -5.9 mm
Y : -46.1 mm
Z : -1445.1 mm
Zoom: 1.75



Window: 294
Level: 16
Map: Ramp

11/16

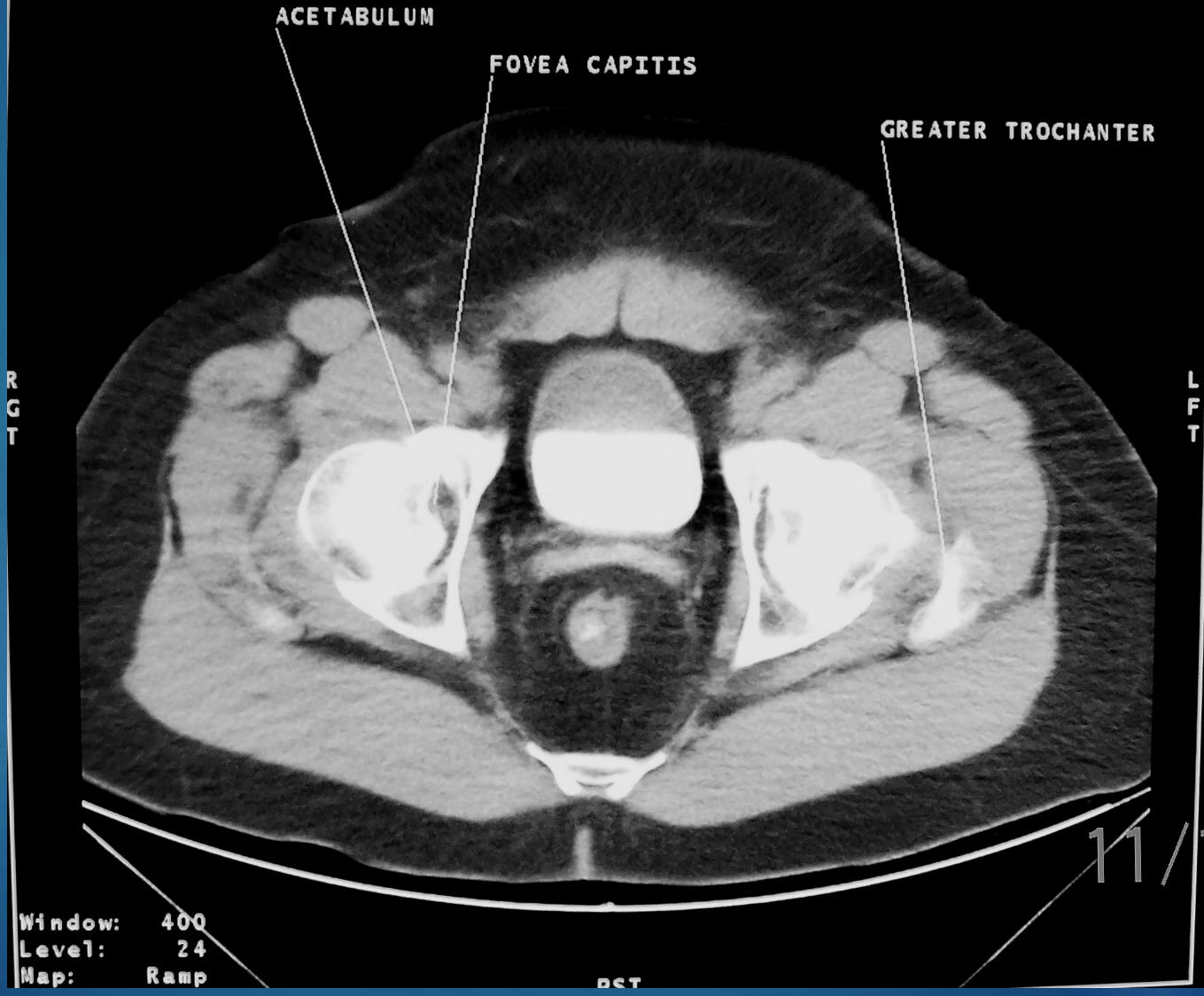PST

BETHESDA OAK HOSPITAL
PQ2000 2619
20-Dec-95 09:38
Patient Name
ID: 0837594
CONT: C+

ANT

2-D #44
Active

Loc: 1445 mm
X : -4.4 mm
Y : -31.3 mm
Z : -1445.1 mm
Zoom: 1.60 X

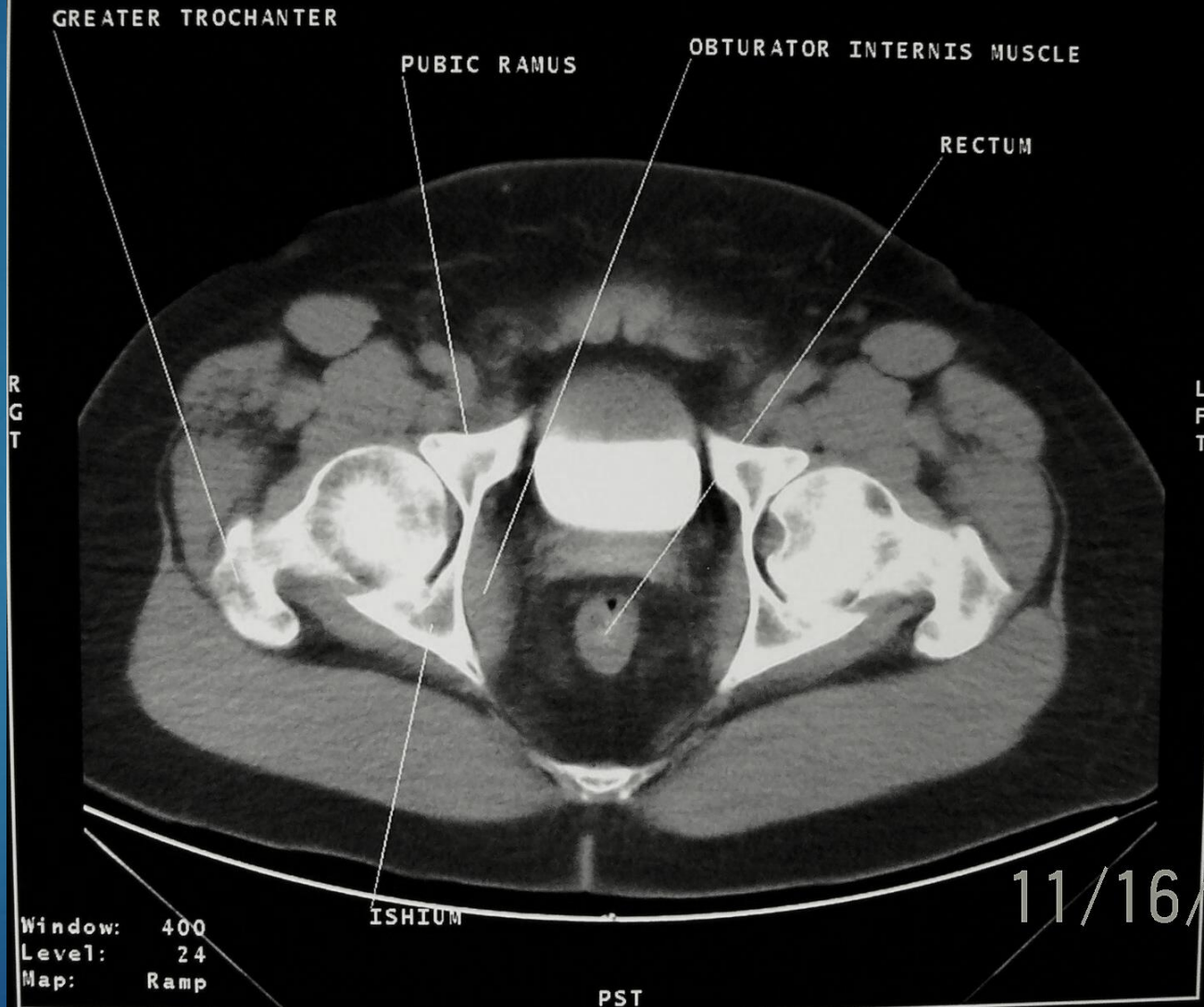


BETHESDA OAK HOSPITAL
PQ2000 2619
20-Dec-95 09:38
Patient Name
ID: 0837594
CONT: C+

ANT

2-D #45
Active

Loc: 1455 mm
X : -4.4 mm
Y : -31.3 mm
Z : -1455.1 mm
Zoom: 1.60 X

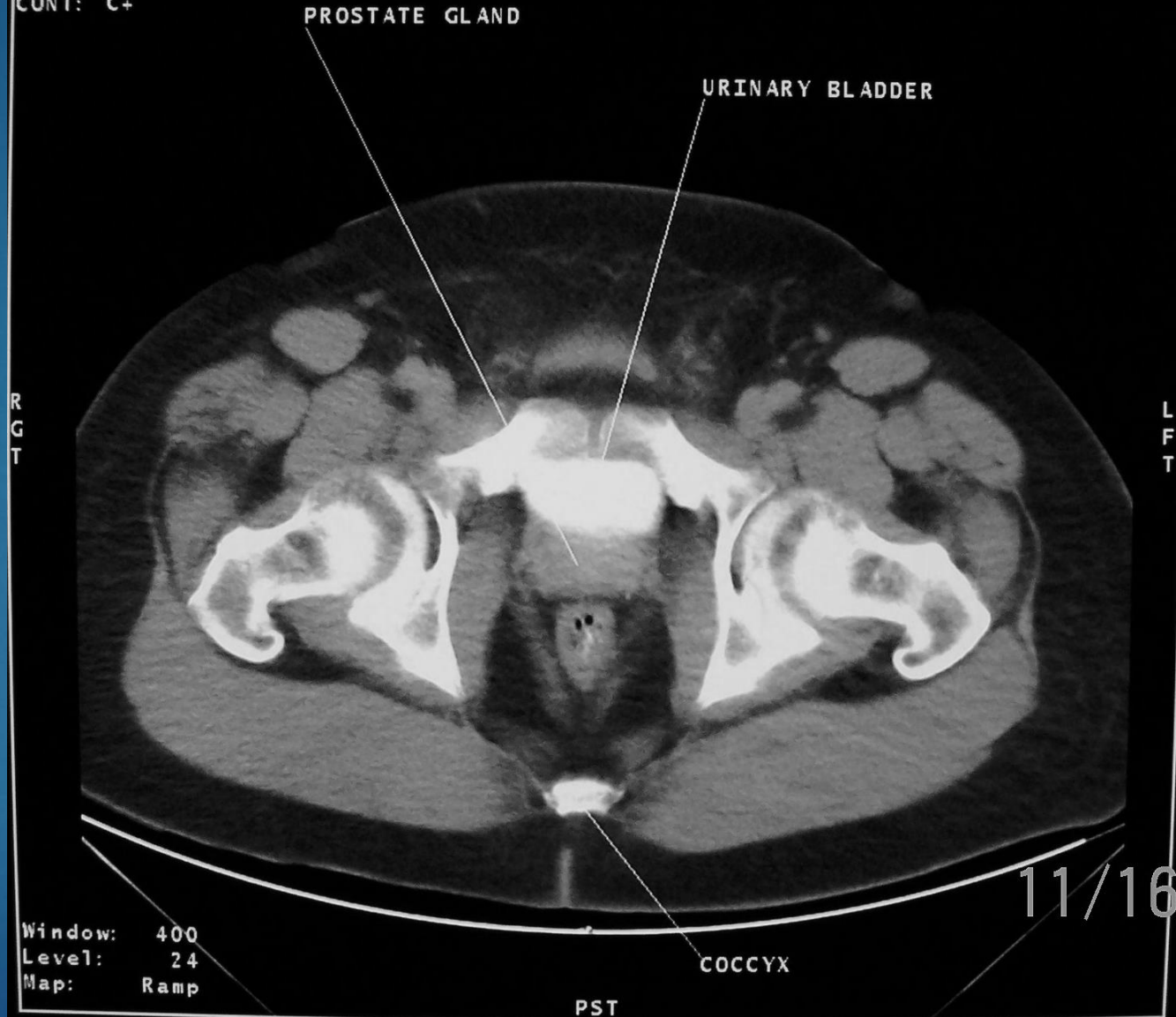

BETHESDA OAK HOSPITAL
PQ2000 2619
20-Dec-95 09:38
Patient Name
ID: 0837594
CONT: C+

ANT

2-D #46
Active

Loc: 1465 mm
X: -4.4 mm
Y: -31.3 mm
Z: -1465.1 mm
Zoom: 1.60 X



Window: 400
Level: 24
Map: Ramp

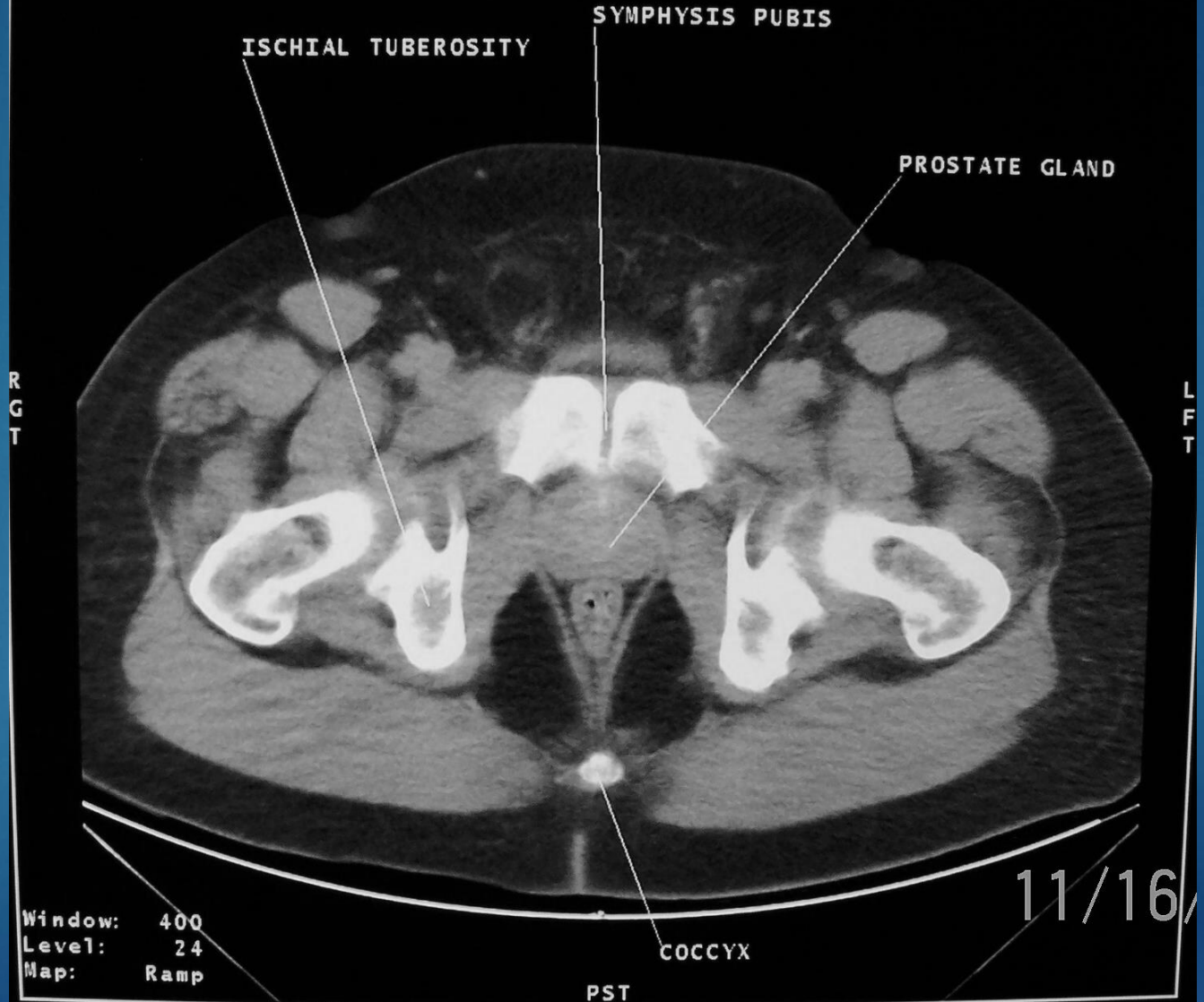
11/16

BETHESDA OAK HOSPITAL
PQ2000 2619
20-Dec-95 09:38
Patient Name
ID: 0837594
CONT: C+

ANT

2-D #47
Active

Loc: 1475 mm
X : -4.4 mm
Y : -31.3 mm
Z : -1475.1 m
Zoom: 1.60 X

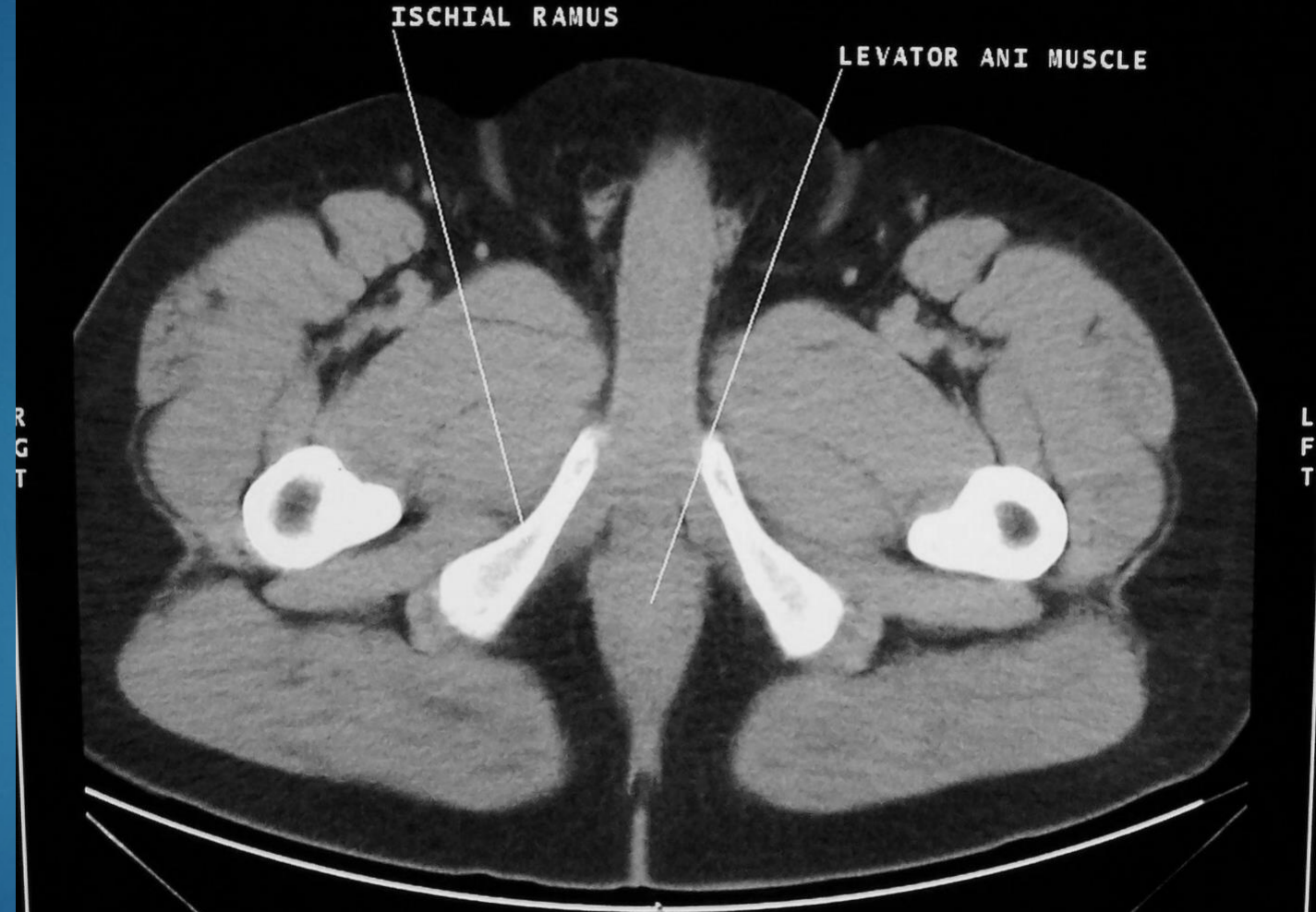


BETHESDA OAK HOSPITAL
PQ2000 2619
20-Dec-95 09:38
Patient Name
ID: 0837594
CONT: C+

ANT

2-D #51
Active

Loc: 1515 mm
X : 0.0 mm
Y : 0.09mm
Z : -1515.1 m
Zoom: 1.60 X

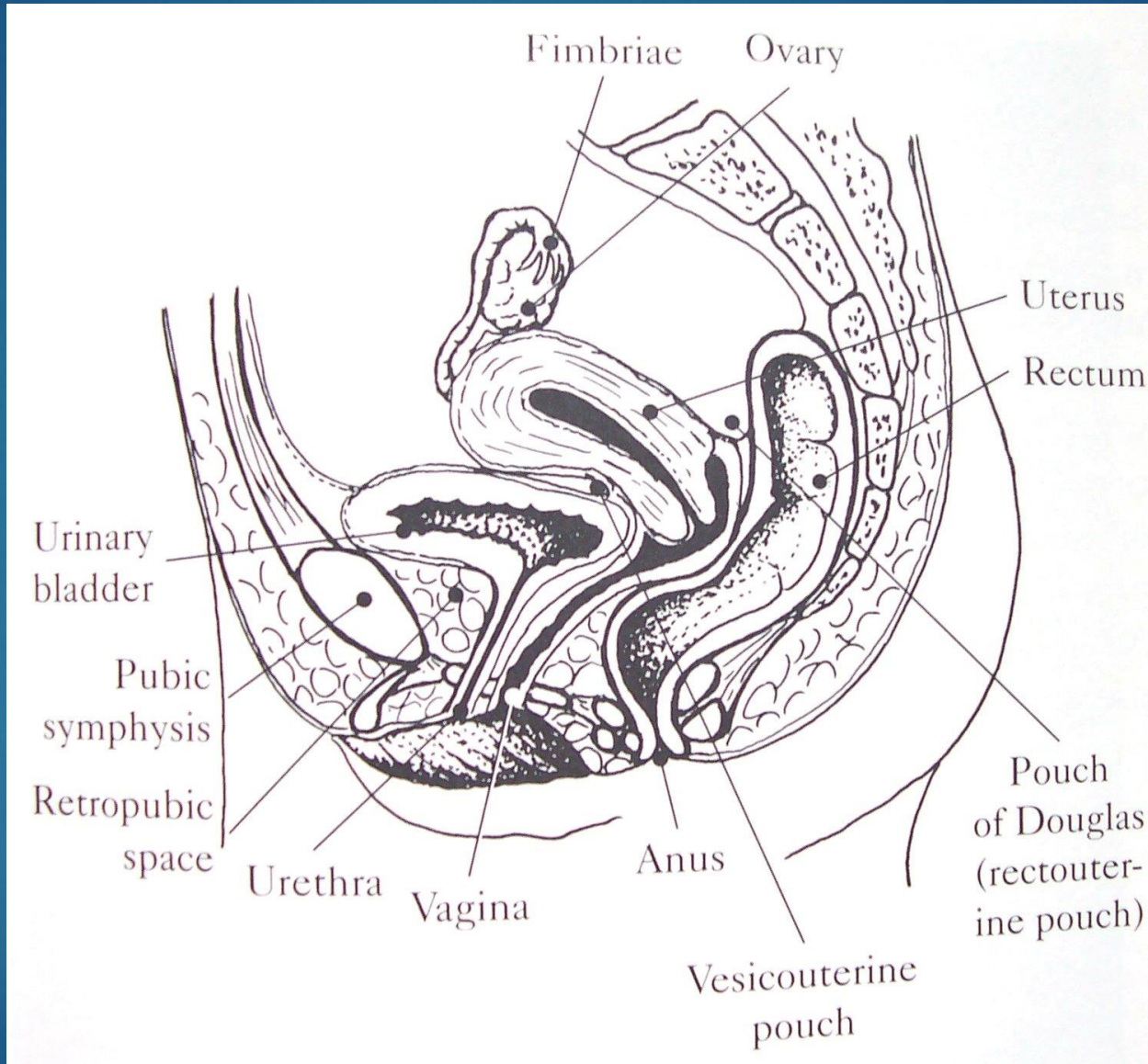


Window: 400
Level: 24
Map: Ramp

PST

11/10

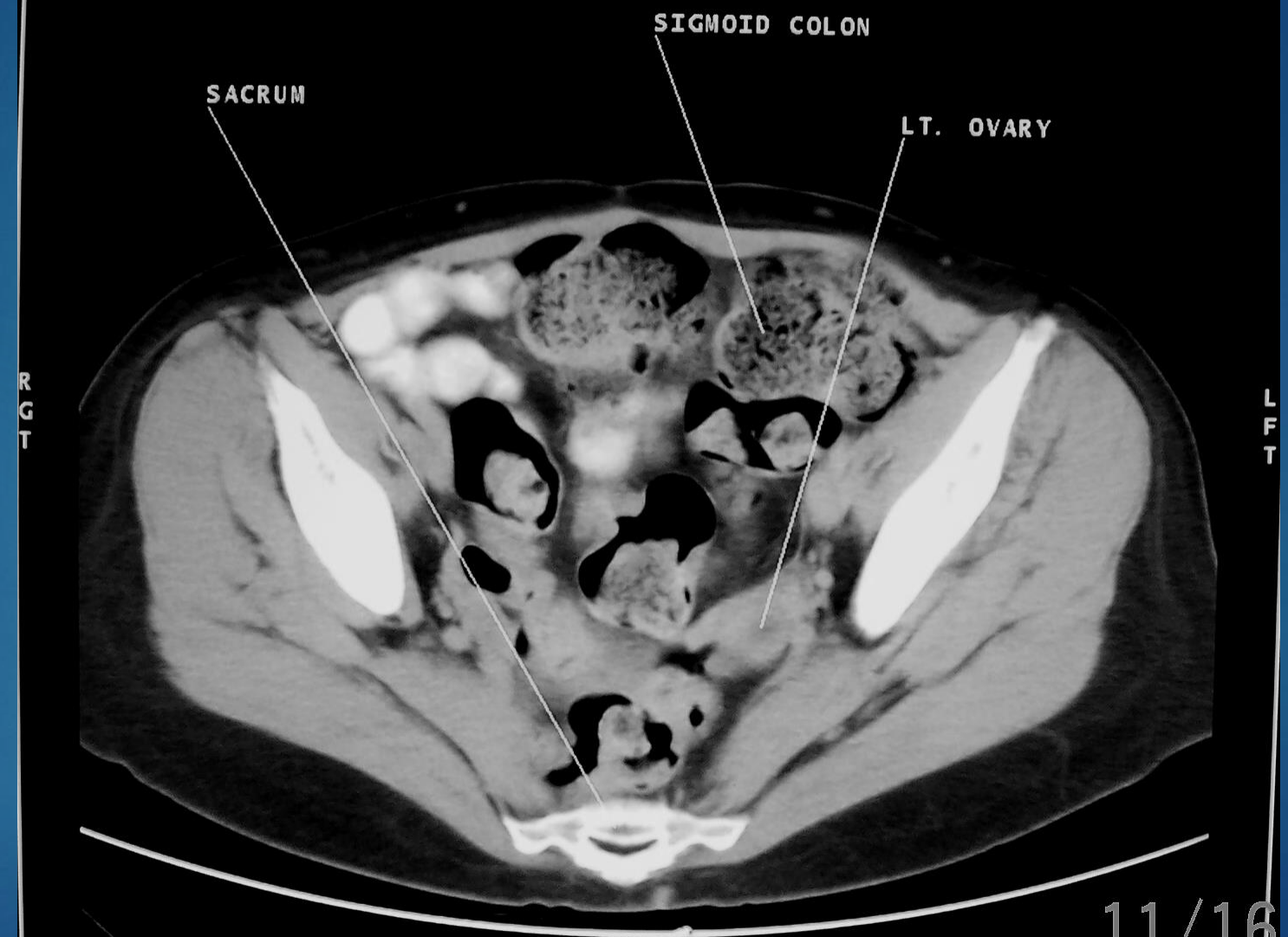Female Pelvic Anatomy



BETHESDA OAK HOSPITAL
PQ2000 3293
05-Mar-96 10:18
Patient Name
ID: 1487461
CONT: C+

ANT 2-D #13
Active

Loc: 1238 mm
X : 0.0 mm
Y : 0.0 mm
Z : -1238.5 mm
Zoom: 1.60 X



Window: 359
Level: 22
Map: Ramp

PST

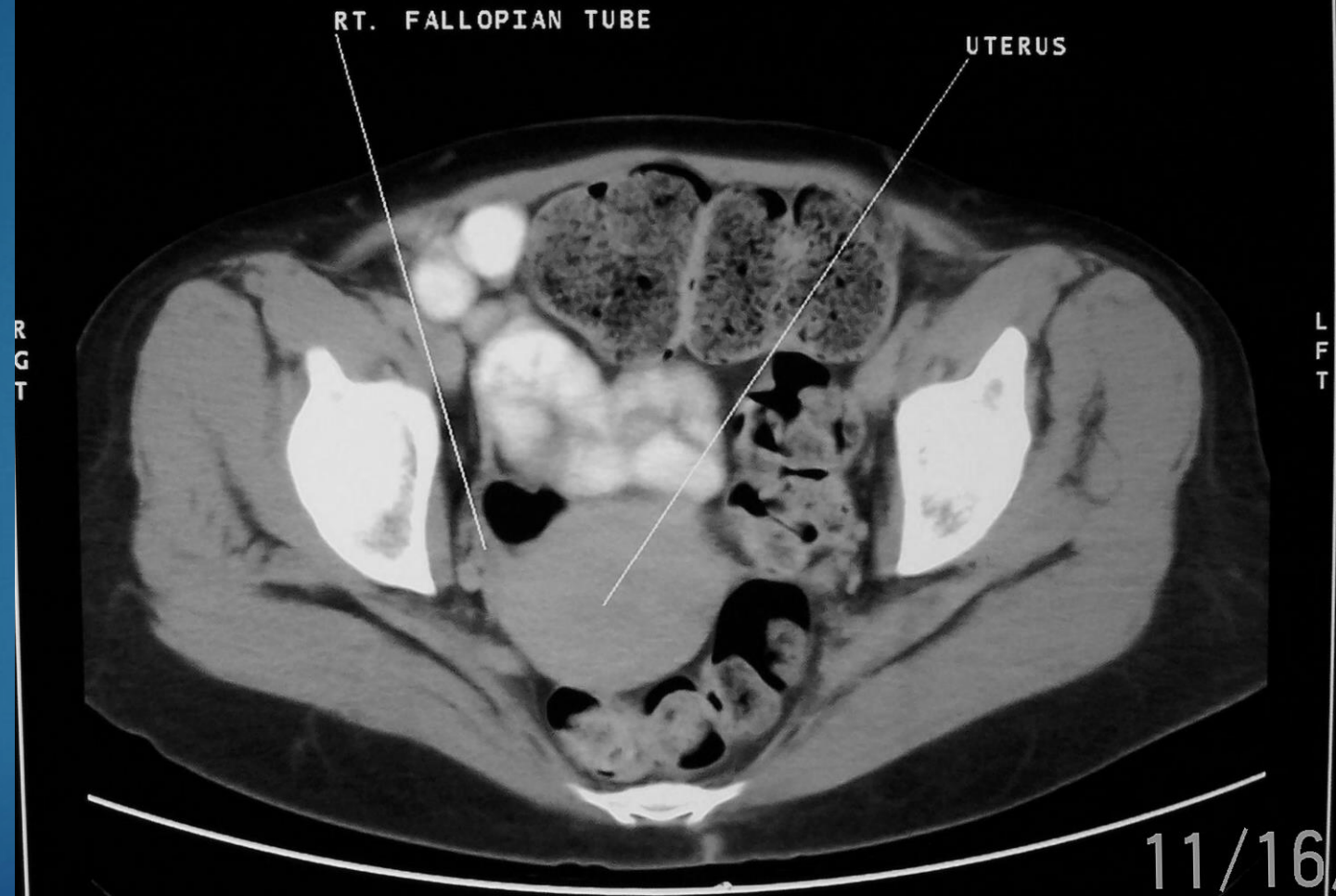
11/16

BETHESDA OAK HOSPITAL
PQ2000 3293
05-Mar-96 10:18
Patient Name
ID: 1487461
CONT: C+

ANT

2-D #15
Active

Loc: 1258 mm
X : 0.0 mm
Y : 0.0 mm
Z : -1258.5 mm
Zoom: 1.60 X



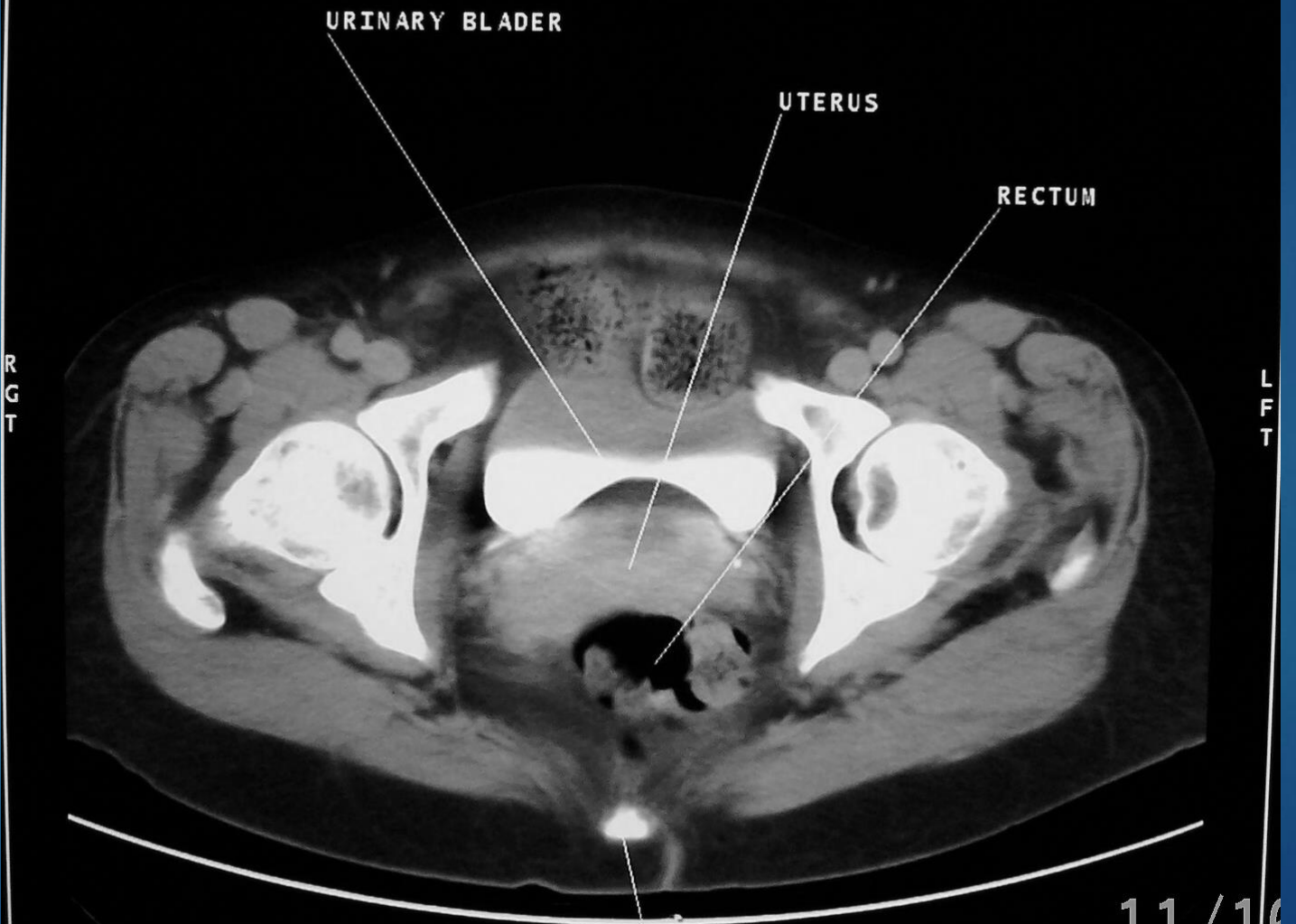
Window: 359
Level: 22
Map: Ramp

PST

BETHESDA OAK HOSPITAL
PQ2000 3293
05-Mar-96 10:18
Patient Name
ID: 1487461
CONT: C+

ANT
Z-D #18
Active

Loc: 1288 mm
X : 0.0 mm
Y : 0.0 mm
Z : -1288.4 mm
Zoom: 1.60 X



Window: 359
Level: 22
Map: Ramp

PST

11/16

BETHESDA OAK HOSPITAL
PQ2000 3293
05-Mar-96 10:18
Patient Name
ID: 1487461
CONT: C+

ANT

2-D #21
Active

Loc: 1318 mm
X : 0.0 mm
Y : 0.0 mm
Z : -1318.6 mm
Zoom: 1.60 X

INFERIOR ASPECT OF U. BLADDER

VAGINA

RECTUM

R
G
T

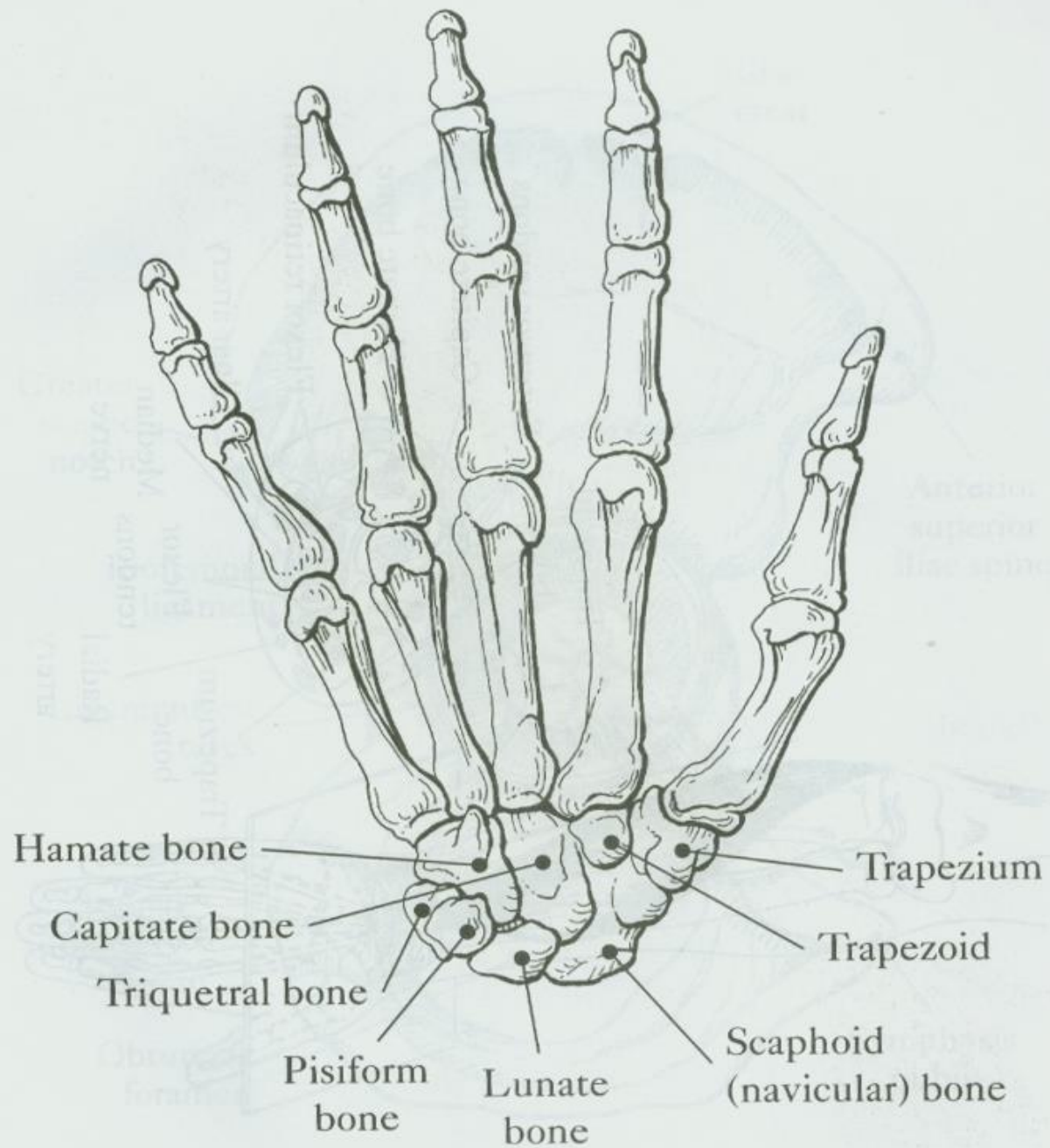
L
F
T

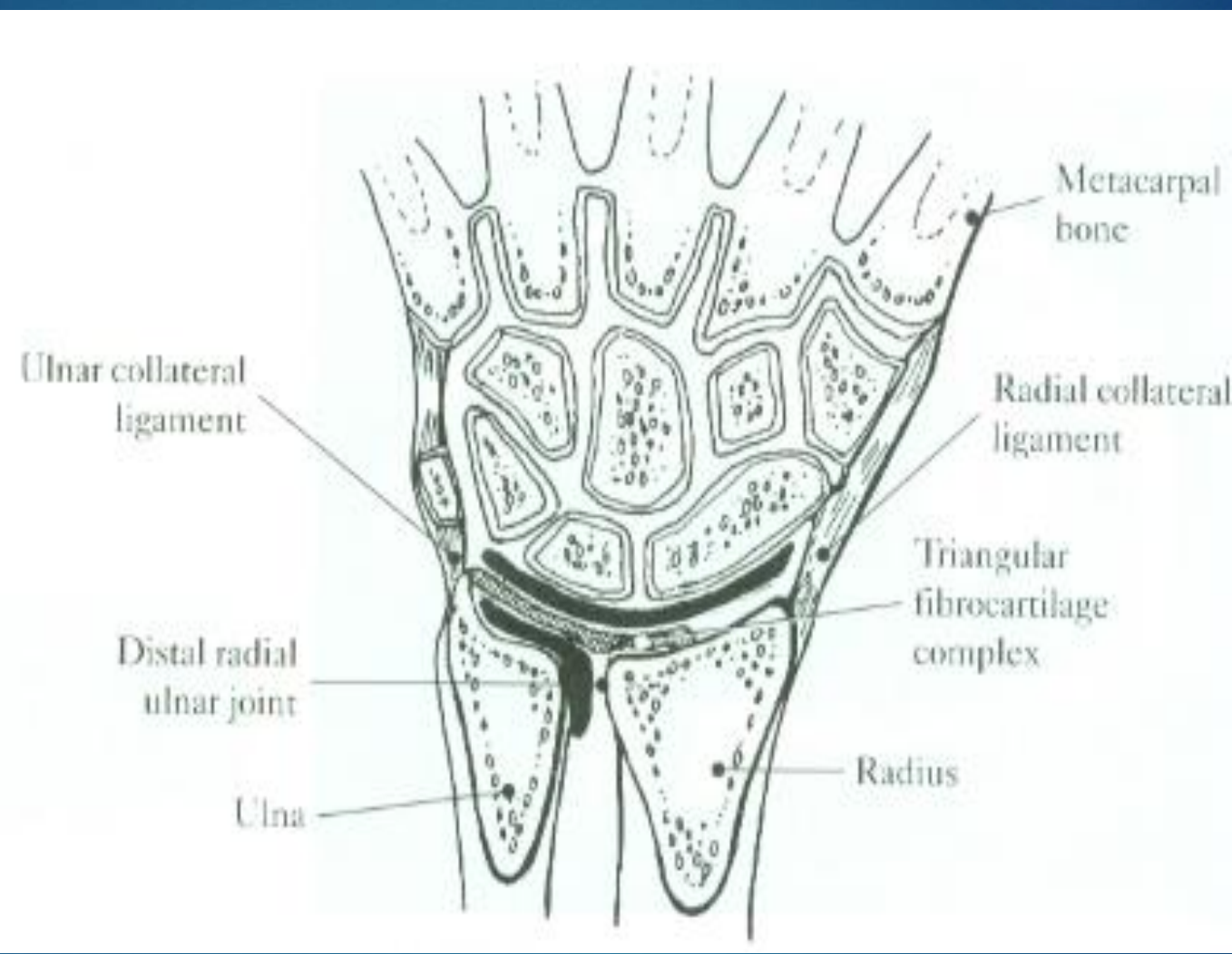
Window: 359
Level: 22
Map: Ramp

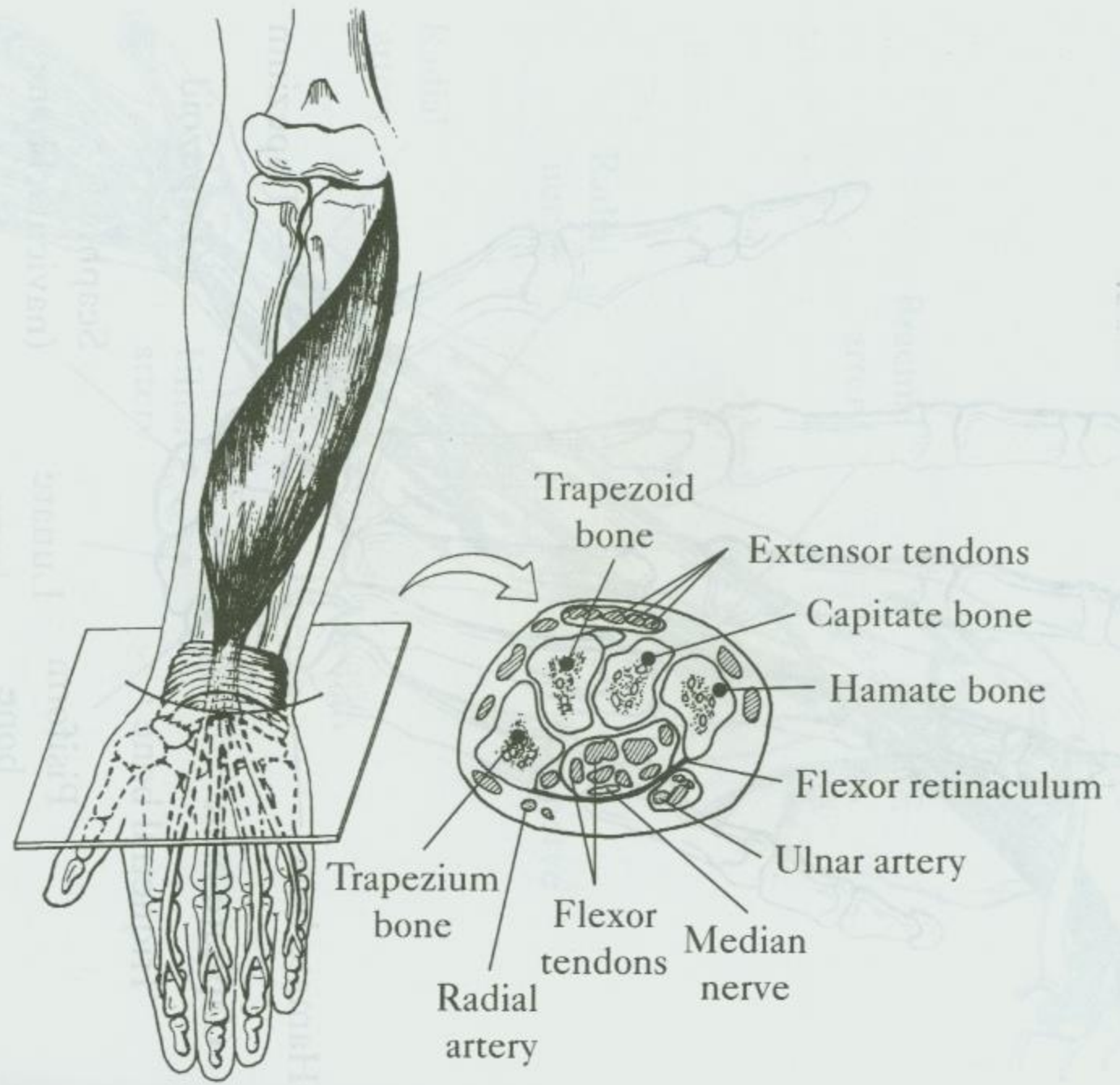
PST

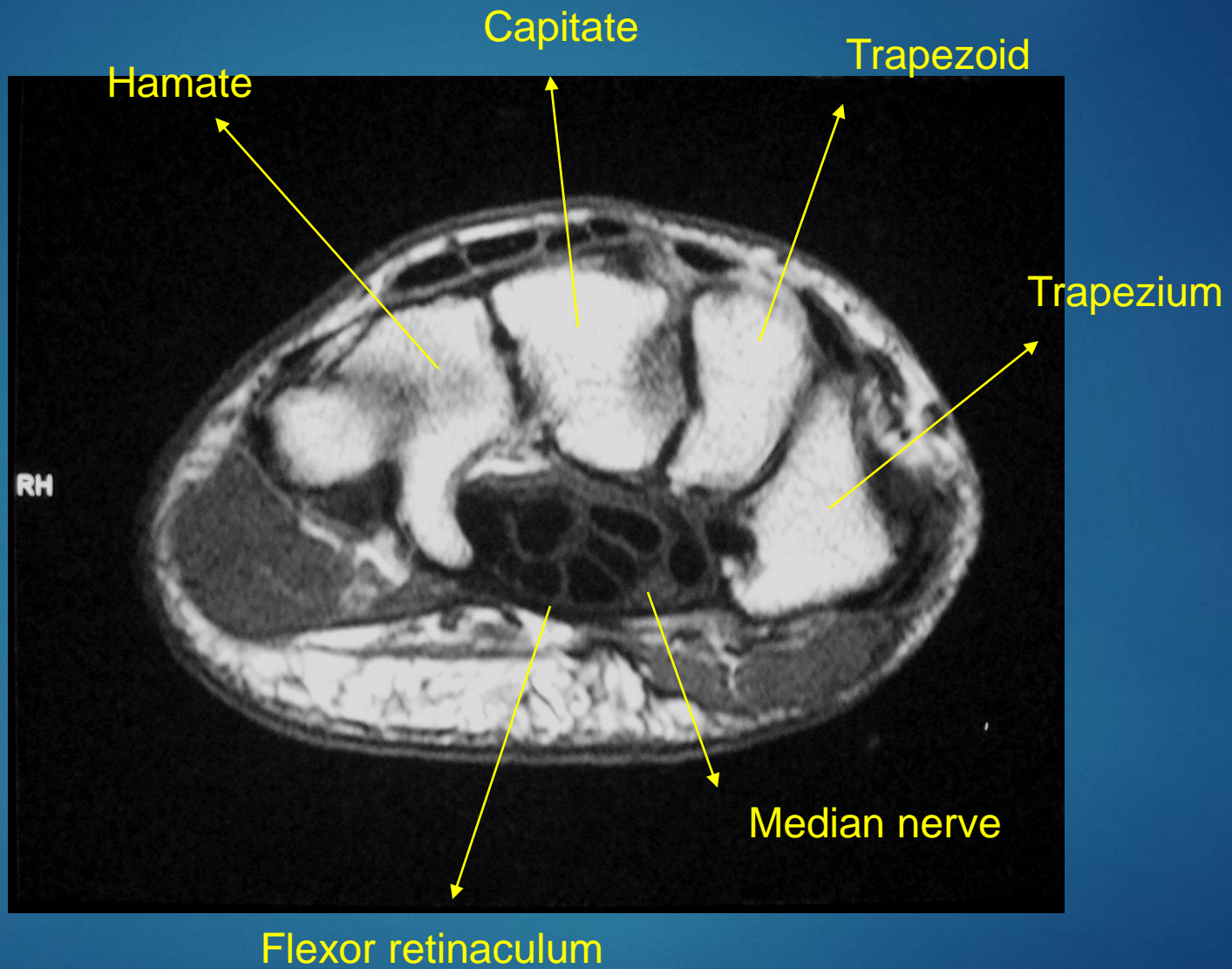
11/16

Anatomy of the Upper Extremity

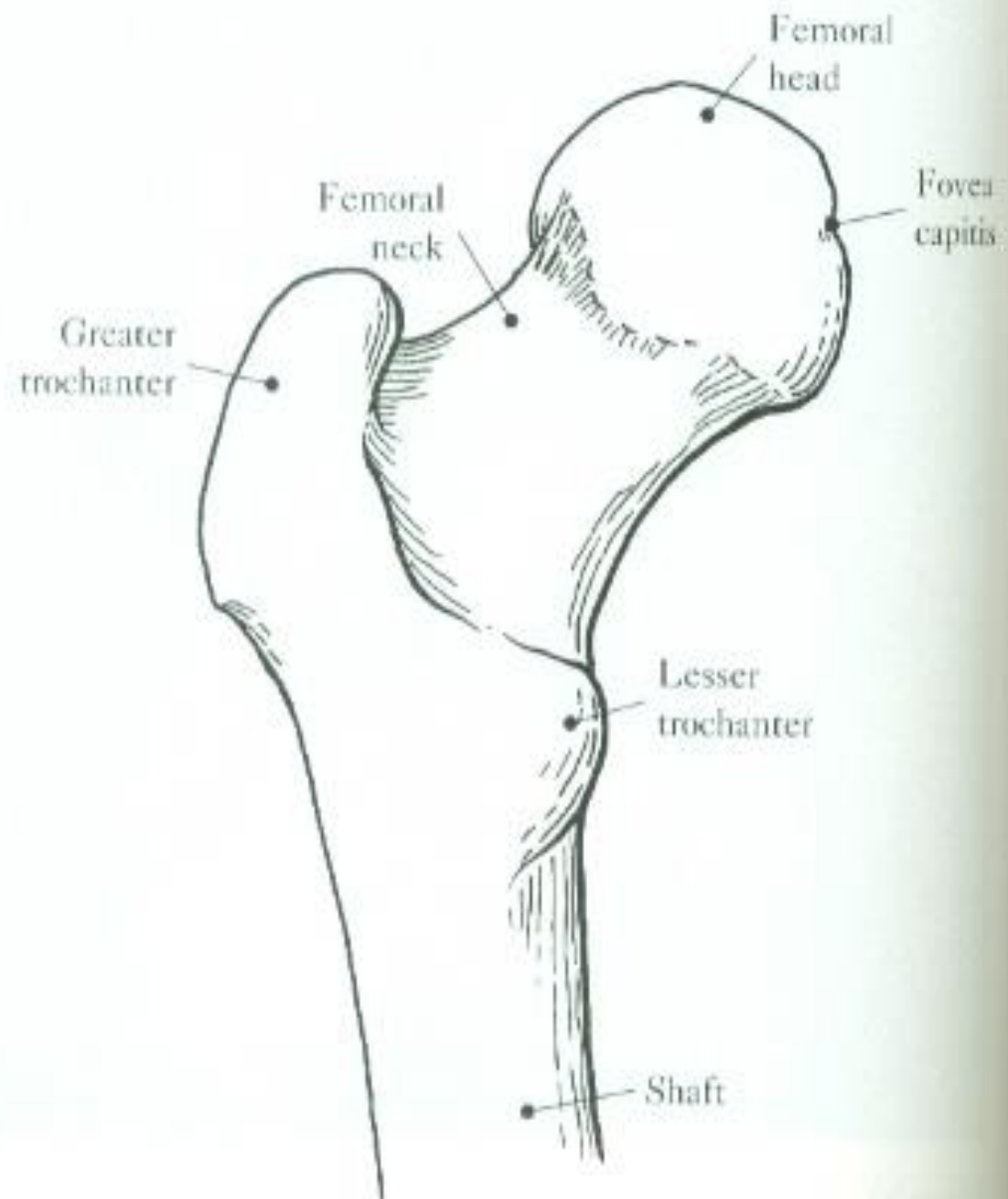


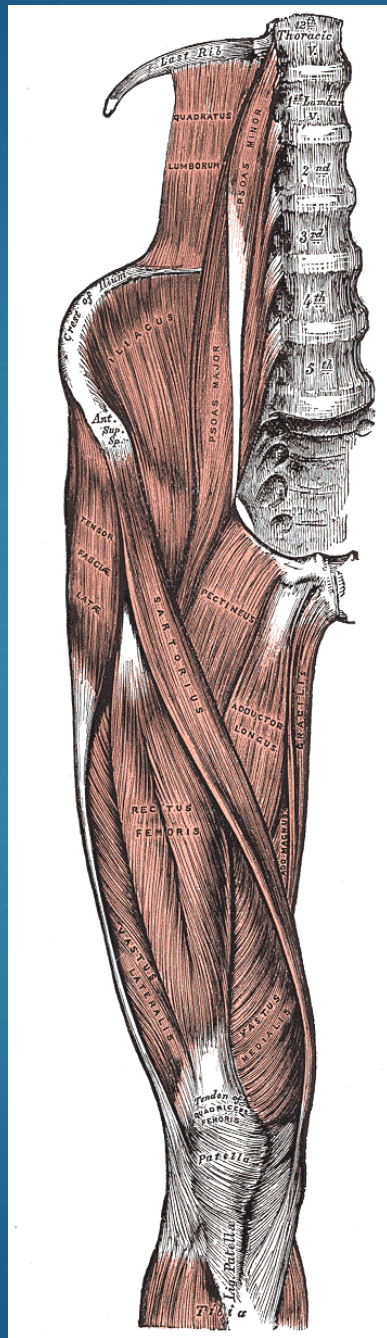




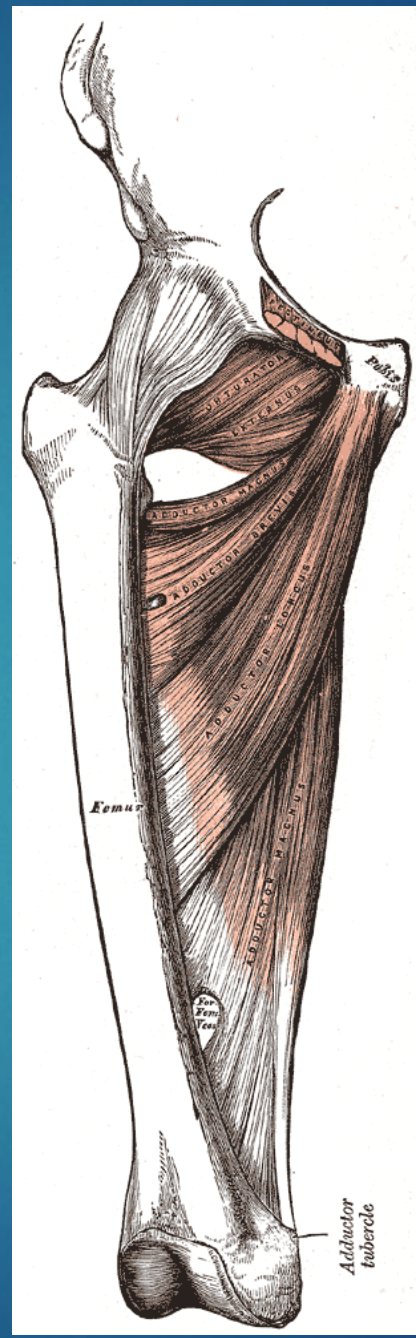


Anatomy of the Lower Extremity Joints





<http://www.bartleby.com/107/127.html>

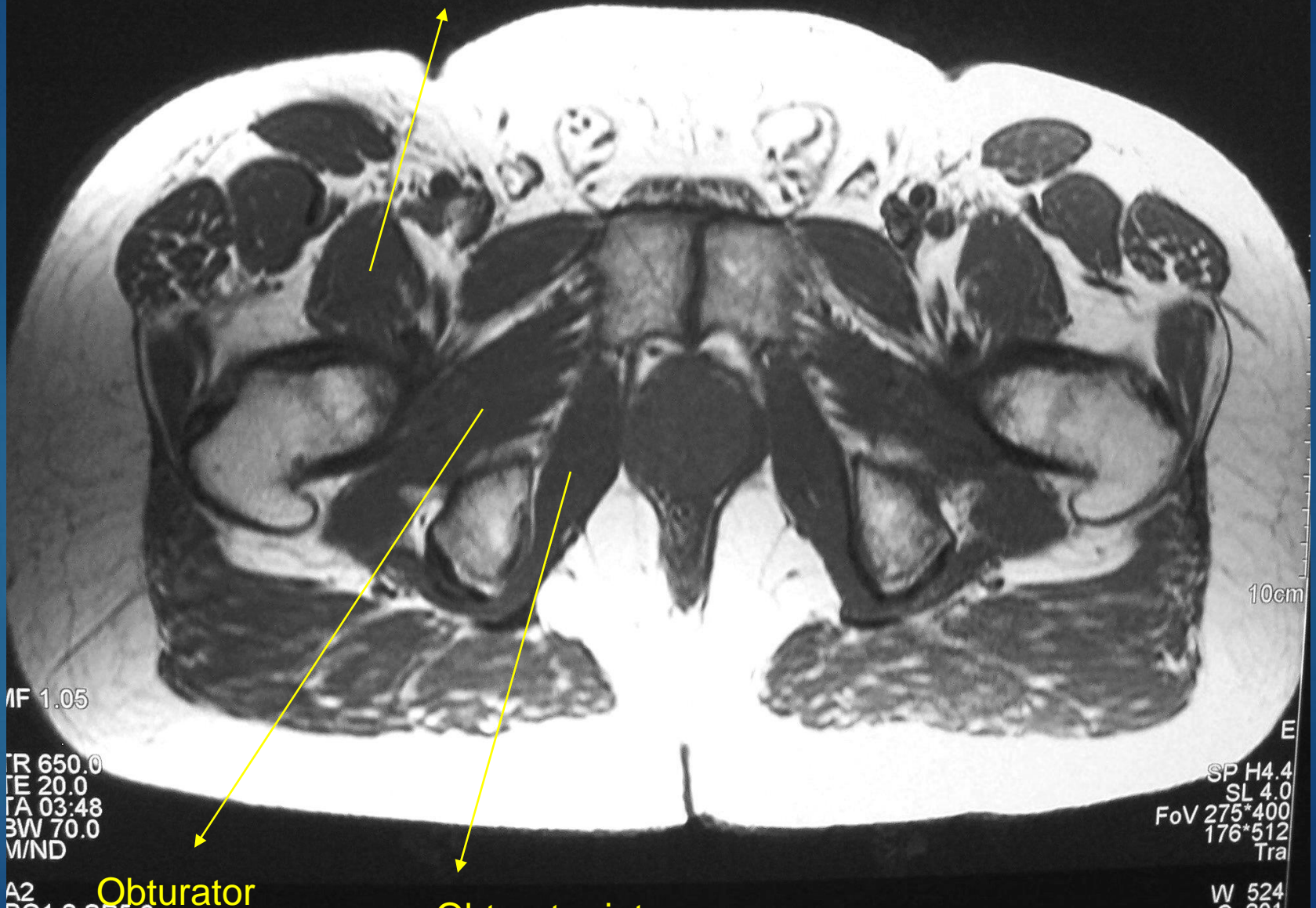

<http://www.bartleby.com/107/illus433.html>

45:40 AM
IMA 7 / 1

MIR 2004/
HF:
+LPI

Iliopsoas



Obturator
externus

Obturator internus

10cm

MF 1.05

TR 650.0
TE 20.0
TA 03:48
3W 70.0
W/ND

A2

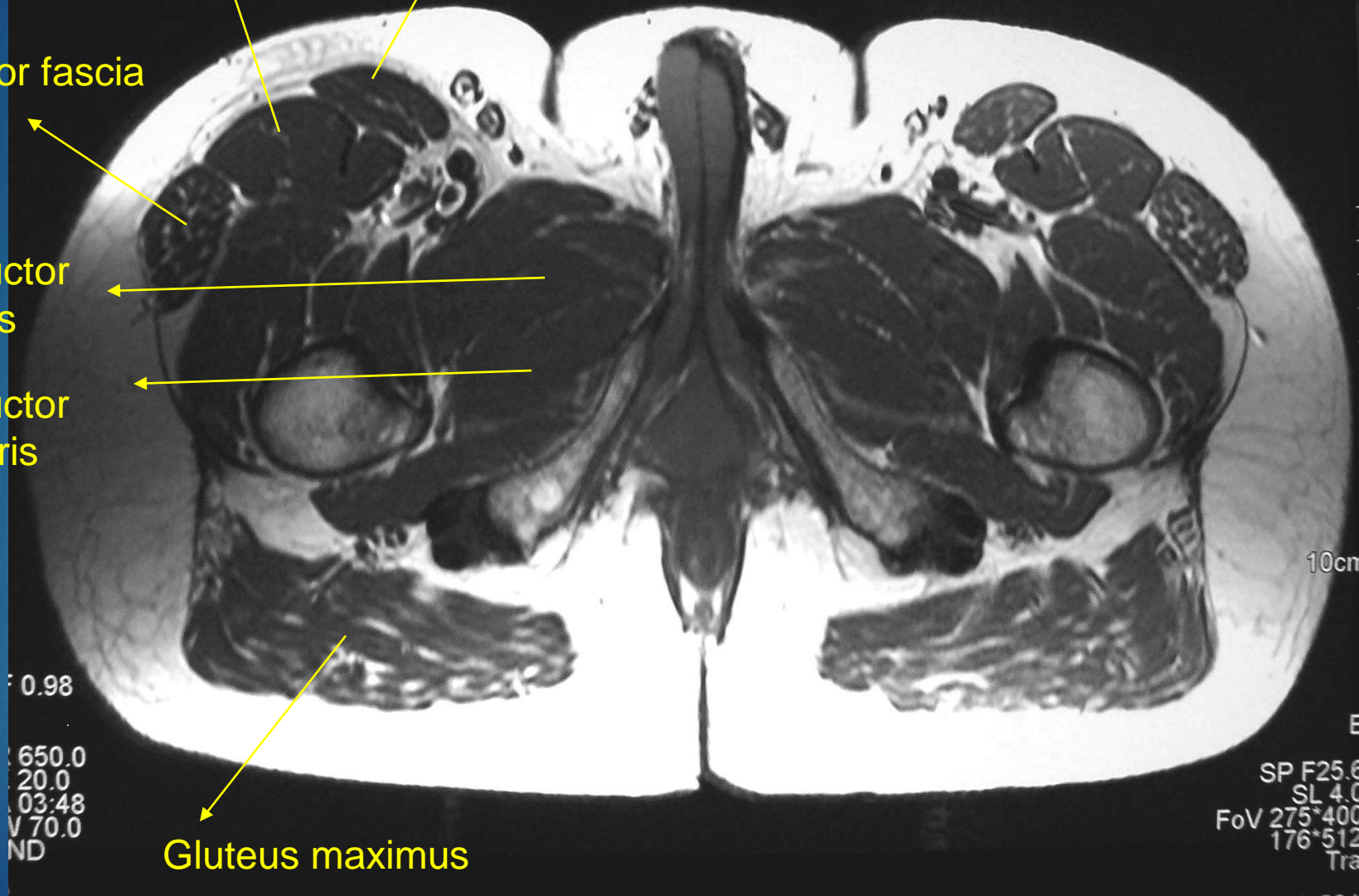
E
SP H4.4
SL 4.0
FoV 275*400
176*512
Tra

W 524

1/3/2005
4:40 AM
IMA 1/1

Symphony
MR 2004A
HFS
+LPH
e

Rectus femoris
Sartorius
Tensor fascia latae
Adductor brevis
Adductor majoris
Gluteus maximus



10cm

0.98
650.0
20.0
03:48
V 70.0
ND

E
SP F25.6
SL 4.0
FoV 275*400
176*512
Tra

Thank you for your kind attention!

I can be contacted at
thaller11@Zoomtown.com